

# Transluminal Nd:YAG Laser Embolysis for Branch Retinal Artery Occlusion

## Retinal Arter Dal Obstrüksüyonu Tedavisinde Transluminal Nd:Yag Lazer Embolizis

Ahmet Taylan YAZICI<sup>1</sup>, Mehmet ÇAKIR<sup>1</sup>, Cengiz ALAGÖZ<sup>2</sup>, Neşe ALAGÖZ<sup>2</sup>,  
Ercüment BOZKURT<sup>1</sup>, Ömer Faruk YILMAZ<sup>3</sup>

Case Report

Olgu Sunumu

### ABSTRACT

The current study was planned to show the efficacy and the safety of transluminal Nd:YAG laser embolysis (TYE) in serious sight threatening branch retinal artery occlusion (BRAO).

Of the three patients treated with TYE, all had good visual recovery with arterial reperfusion. No complication related to procedure was observed. TYE, in limited number of cases, has been shown to be an effective treatment technique in BRAO.

**Key Words:** Branch retinal artery occlusion, treatment, transluminal Nd: YAG laser embolysis.

### ÖZ

The current study was planned to show the efficacy and the safety of transluminal Nd:YAG laser embolysis (TYE) in serious sight threatening branch retinal artery occlusion (BRAO). Of the three patients treated with TYE, all had good visual recovery with arterial reperfusion. No complication related to the procedure was observed. TYE, in a limited number of cases, has been shown to be an effective treatment technique in BRAO.

**Key Words:** Branch retinal artery occlusion, treatment, transluminal Nd:YAG laser embolysis.

Ret-Vit 2010;18:159-162

### INTRODUCTION

Branch retinal artery occlusion (BRAO) is an acute pathology presenting with sudden visual loss without pain and occurring commonly as a result of emboli or cholesterol plaques. BRAO appears typically as a localized whitening of retina along the distribution of the obstructed artery. It results in a complete or partial retinal ischemia.<sup>1,2</sup>

No agreement has been made on the treatment approaches in retinal artery occlusion (RAO). Hyperosmotic agents and paracentesis decreasing intraocular

pressure and improving capillary perfusion, ocular massage as an attempt to replace the embolus to more distant part of the artery, hyperbaric oxygen therapy,<sup>3</sup> low intensity argon laser photocoagulation<sup>4</sup> and intravenous prostaglandin E infusion<sup>5</sup> are some of the treatment methods that have been applied. After Opremcak and Benner demonstrated a good functional recovery following Nd:YAG laser embolysis in 2002,<sup>6</sup> other studies and reports have been made on the technique.

The current study was planned as a small prospective case series to show the efficacy and the safety of Nd:YAG laser embolysis in BRAO.

Geliş Tarihi : 06/11/2009

Kabul Tarihi : 30/12/2009

Received : December 06, 2009

Accepted : September 30, 2009

\* 2008 MEDIRETINA Kongresi'nde Tebliğ Olarak Sunulmuştur.  
1- Beyoğlu Göz Eğitim ve Araştırma Hastanesi İstanbul, Uzm. Dr.  
2- Beyoğlu Göz Eğitim ve Araştırma Hastanesi İstanbul, Asist. Dr.  
3- Beyoğlu Göz Eğitim ve Araştırma Hastanesi İstanbul, Prof. Dr.

1- M.D., Beyoğlu Eye Education and Research Hospital İstanbul/TURKEY  
YAZICI A.T., ahmettaylan19@hotmail.com  
CAKIR M., drmcakir@hotmail.com  
2- M.D. Asistant, Beyoğlu Eye Education and Research Hospital İstanbul/TURKEY  
ALAGOZ C., alagozcengiz@gmail.com  
ALAGOZ N., alagoznese@gmail.com  
3- M.D. Professor, Beyoğlu Eye Education and Research Hospital İstanbul/TURKEY  
YILMAZ Ö.F., ofyilmaz@yahoo.com

**Correspondence:** M.D. Ahmet Taylan YAZICI  
Beyoğlu Eye Education and Research Hospital, Kuledibi İstanbul/TURKEY

## MATERIAL AND METHOD

Three eyes of three patients with BRAO presenting with visual acuity of 20/100 or worse and visible transluminal emboli were involved in this case series. The thorough ophthalmologic examination, fluorescein angiography (FA) and optical coherence tomography (OCT) of the eyes were performed. All patients were informed about the procedure and possible complications. No medical treatment was given to the patients nor was any intervention like paracentesis performed. Following topical anesthesia, a macular contact lens was placed and transluminal Nd:YAG laser embolysis (TYE) was performed directly to the arterial segment embedding the embolus that had been previously localized and verified by FA. The energy was set as low as 0.8 mJ and gradually increased by 0.1 mJ.

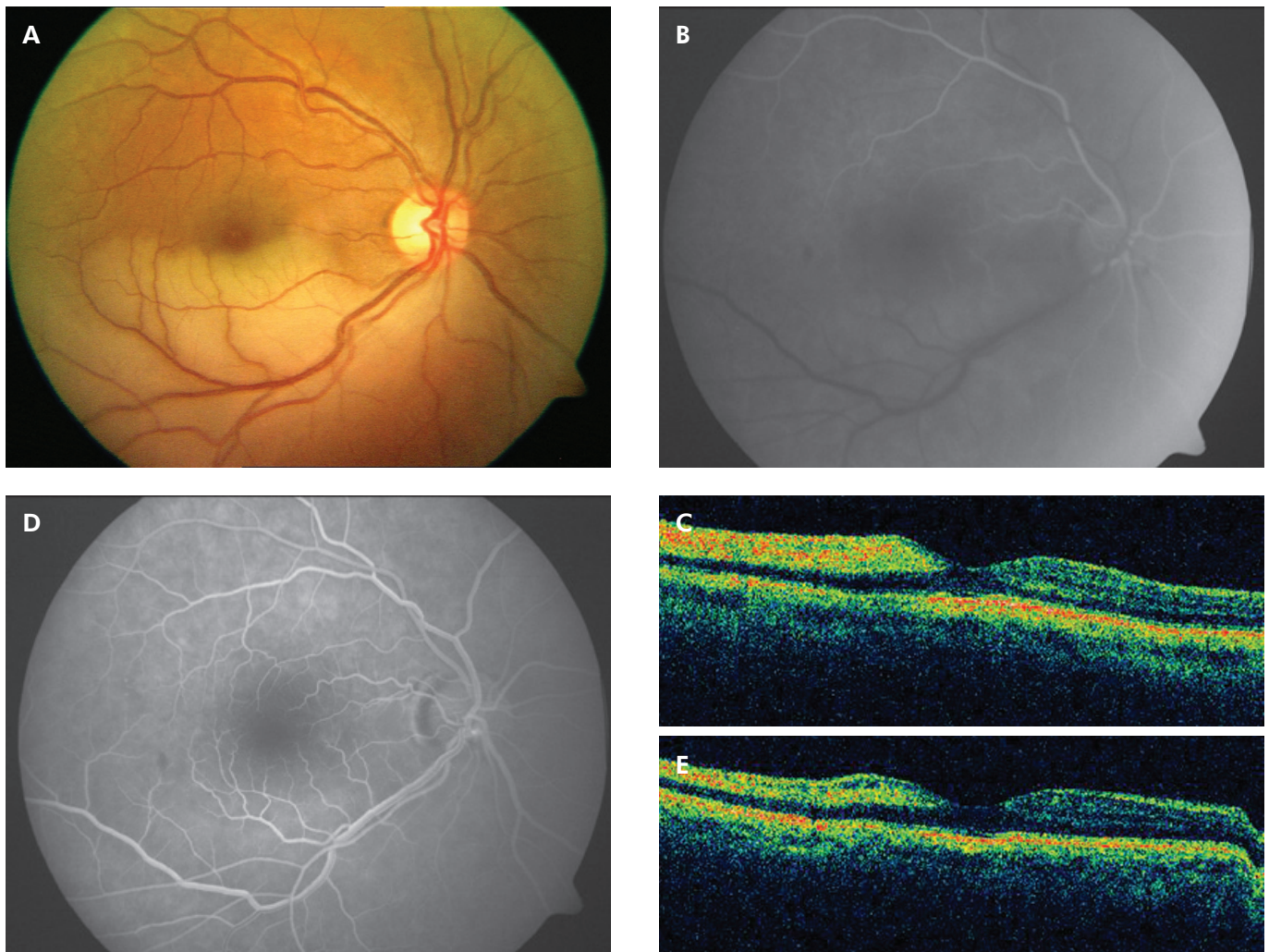
Visual acuity (VA), FA examination and OCT images were recorded at day1, week1, month1 and the final visit.

## CASE REPORT

### Case 1

A 64-year-old man presented to the emergency department with a complaint of a sudden decrease in his VA in the right eye accompanied by a scotoma in his upper half of the visual field of 48 hours duration. He had an unremarkable medical history. On examination his best corrected VA was 20/100, and a small degree of nuclear sclerosis was present in the affected eye. Fundus examination revealed paleness on the inferior temporal retina (Figure 1a) and a visible transluminal embolus lodged at the arterial bifurcation. FA demonstrated a filling defect in the inferior temporal artery just distal to the bifurcation (Figure 1b), and retinal thickening and increased reflectivity were present on the OCT images (Figure 1c).

The patient underwent TYE to his right eye. A total of 10 pulses of 0.8-1.2 mJ (total 8.4 mJ) were delivered directly to the embolus via a macular contact lens.



**Figure 1:** (a) Color fundus photograph of Case 1 at presentation. Paleness along the inferior temporal artery distribution in the right eye is noted. (b) Fluorescein angiogram of the same patient, demonstrating a filling defect in the inferior temporal artery just distal to the bifurcation. Note the wedge shaped capillary nonperfusion area along the distribution of the artery. (c) The optical coherence tomogram (OCT) of the same patient at presentation, demonstrating retinal thickening in the inferior temporal artery region. (d) Fluorescein angiogram of the same patient one week following the transluminal Nd:YAG laser embolysis (TYE). Reperfusion of the artery with a small residual embolus at the arterial bifurcation is seen. Note the ischemia resolved after the procedure. (e) OCT of the same patient one week following the TYE. Marked decrease in the retinal thickening is seen.

No complication related to TYE occurred. The day after the procedure his best corrected VA measured 20/40. On FA examination the embolus at the arterial bifurcation was noted to be fragmented and only a small residual embolus at the same location was seen. Reperfusion of the artery was observed (Figure 1d). His 1st week and 1st month examination revealed 20/30 VA and there was a marked decrease in the retinal thickening on OCT (Figure 1e).

### Case 2

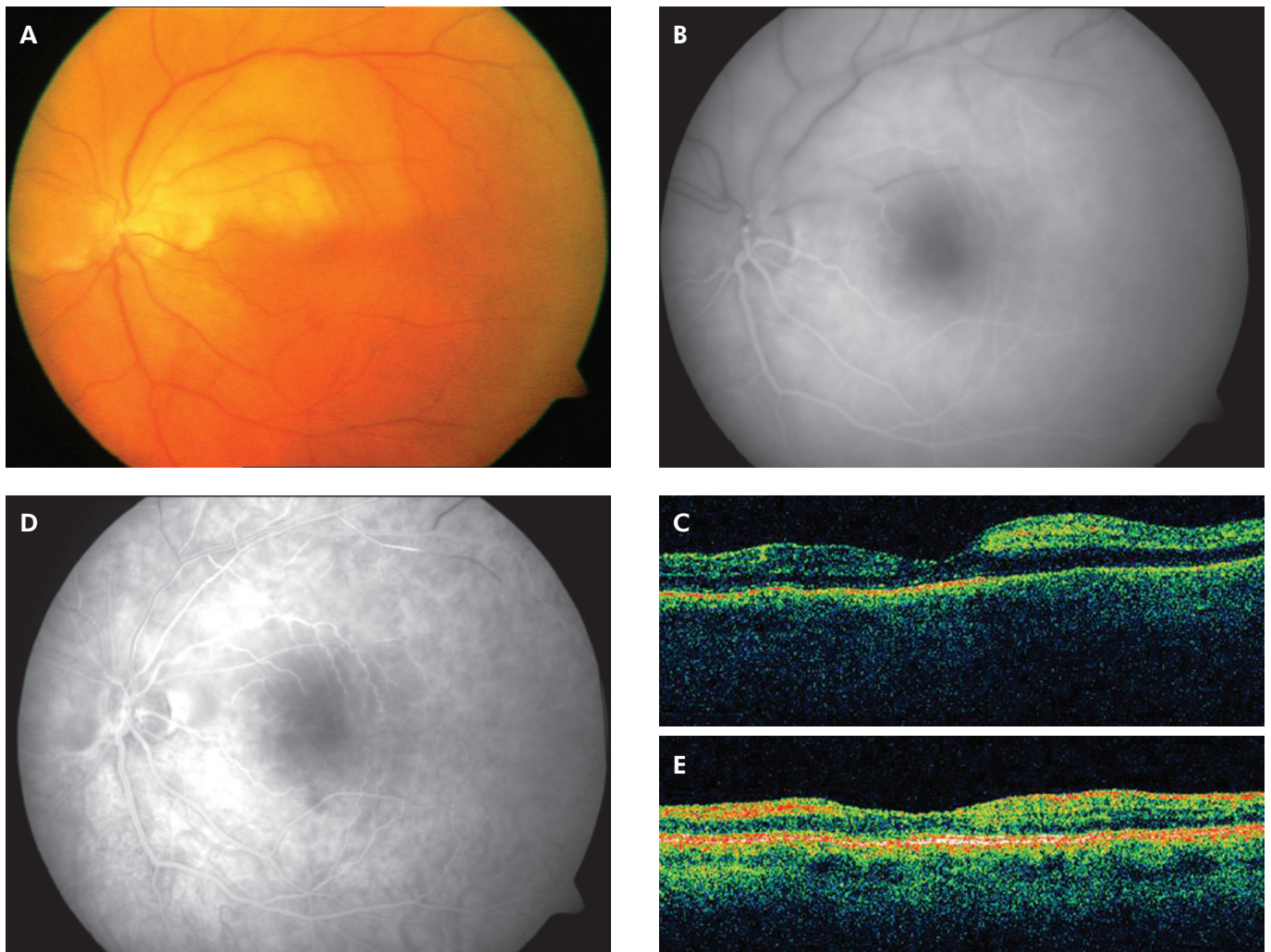
A 60-year-old woman presented with an acute loss of vision in her left eye of 6 hours duration. Her medical history was remarkable for systemic hypertension regulated on medication. On her ophthalmologic examination her best corrected VA was noted to be 20/400. No significant pathology was present in the anterior segment evaluation. Whitening of retina in the superior temporal quadrant and an embolus at the superior branch of retinal artery distant to the bifurcation was present (Figure 2a).

FA showed a filling defect in the superior temporal artery (Figure 2b). OCT imaging revealed retinal thickening in the superior half and increased reflectivity in the same region (Figure 2c).

TYE was applied to her left eye. A macular contact lens was used to focus and deliver 10 subsequent pulses of 0.8-1.4 mJ Nd:YAG laser to the embolus (total 9.2 mJ), while the embolus was noted to disrupt. No complication was encountered. On the first day after the laser treatment her VA improved to 20/40. FA showed partially restored arterial flow distant to occlusion with small residues of the embolus spread in the lumen (Figure 2d). At week 1 and month 1 visit the patient maintained 20/40 VA and retinal edema resolved to a great extent as showed by OCT imaging (Figure 2e).

### Case 3

A 35-year-old woman presented to the emergency department with a sudden decrease in VA in her right eye



**Figure 2:** (a) Color fundus photograph of Case 2 showing retinal whitening in the superior temporal quadrant and an embolus at the superior branch of the retinal artery lodged at the bifurcation. (b) Fluorescein angiogram of the same patient, demonstrating a filling defect in the superior temporal artery and the embolus. (c) Optical coherence tomogram (OCT) of Case 2 demonstrating retinal edema in the superior temporal retinal artery region. (d) Fluorescein angiogram of the same patient one week following the transluminal Nd:YAG laser embololysis (TYE). (e) OCT of the same patient one week following the TYE. Marked decrease in the retinal thickening is seen.

occurring 12 hours earlier. She had no remarkable past medical history except oral contraceptive use. On initial examination she had 20/100 VA with no associated significant pathology in her anterior segment. An embolus was observed at the bifurcation of inferior temporal artery and paleness in the corresponding region. Increased retinal thickness and high reflectivity were noted on OCT imaging.

Thereafter, TYE was performed to the same eye with a pulse of 0.8 mJ that was gradually increased up to 1.2 mJ (total of eight pulses and 7.4 mJ). No complication related to the TYE was noted. In the following day VA improved to 20/40 while a good arterial perfusion in the affected branch was seen on FA. There was no evidence of an intraluminal embolus. At week 1 visit the VA had further improved to 20/20. OCT images showed good resolution of the retinal thickening. The patient maintained her VA in the 1<sup>st</sup> and 3<sup>rd</sup> month visits.

## DISCUSSION

Despite a variety of interventional approaches, there has not been yet a satisfactory technique in RAO treatment. RAO is an acutely developing pathology that may have permanent visual loss unless treated without delay and especially if the extend of retinal ischemia is great at the presentation.

While patients with central RAO have poor visual outcome, most patients with BRAO maintain a favorable visual prognosis. Without any treatment, final VA was found to be 20/40 or better in 80% of BRAO patients in an observational study involving 30 subjects.<sup>7</sup> Likewise Ros et al, in a study involving a large series of 201 eyes with BRAO reported 20/40 or better final VA in 75% cases. In addition, there was no significant difference between the results of treated and non treated groups.<sup>8</sup> Mason JO 3rd et al. pointed out the initial VA being the most important prognostic factor determining the final visual function.<sup>9</sup> In this retrospective study including 52 BRAO subjects, 60% of the eyes had final VA of 20/40 or better without any treatment. However, only 2 out of 14 eyes with initial VA of 20/100 or worse have regained vision over time.<sup>9</sup> Thus, poor presenting vision seemed to be the single most important factor indicating treatment in BRAO.

TYE has been used in the treatment of both central and branch retinal artery occlusion, and resulted in prompt visual improvement besides capillary reperfusion.<sup>5,6,10,11</sup> In all cases the initial VA of 20/100 or worse improved to 20/40 and better. The largest study including 19 sight-threatening (20/70 or worse) cases conducted by Opremcak et al. showed Snellen VA improvement by an average of 4.7 lines in 17/19 (89%) patients after TYE.<sup>12</sup> The results in our study support the good visual improvement following TYE in BRAO that have poor initial VA. Three eyes presenting with VA of 20/100 or worse due to BRAO and visible emboli on funduscopy were successfully treated by TYE. All had good visual recovery one day after the treatment, and the VA have improved much better in the later period.

The infrared rays of Nd:YAG laser penetrate through the vessel and cause a rapid thermal expansion and thus photodisruption and fragmentation of the embolus.<sup>6</sup> Vitreous or subretinal hemorrhage, retinal tear, epiretinal membrane and choroidal neovascular membrane are the potential complications to occur.<sup>6</sup> However, the most frequent complication reported is vitreous or subretinal hemorrhage in which case pressure to globe applied by the contact lens is mostly enough to cease the blood flow.<sup>5,12</sup> The small amount of vitreous hemorrhage is observed to clear easily in the follow up. The visual results appeared good even after vitrectomy for subretinal hemorrhage after TYE.<sup>12</sup> In the current study, no complication related to TYE was observed.

The major limitations of the present study are the small number of cases involved and the short follow-up time. Longer follow-up periods are needed to see whether any late complications like secondary epiretinal membrane formation or choroidal neovascularization will occur. Because the patients were all treated in a very short time from the onset, we also do not have an experience with RAO of delayed presentation. Further studies should be conducted to confirm the efficacy and safety of TYE. Knowing the visually devastating nature of RAO, a proper treatment to restore the vision should be considered. As there is no other treatment method proven to have more benefit than TYE, this technique is worth being used in the treatment of RAO presenting with poor visual prognosis. In conclusion, Nd: YAG laser embolysis seems to be an effective technique at restoring retinal blood flow and regaining the visual function in retinal artery occlusion. In subjects having poor initial visual acuity, transluminal Nd:YAG laser embolysis might be a promising initial treatment approach.

## REFERENCES/KAYNAKLAR

1. Brown CG, Maragal LE.: Central retinal artery obstruction and visual acuity. *Ophthalmology*. 1982;89:14-19.
2. Patz A.: Clinical and experimental studies on retinal neovascularization. *Am J Ophthalmol*. 1982;94:715-743.
3. Weinberger AW, Siekmann UP, Wolf S et al.: Treatment of Acute Central Retinal Artery Occlusion (CRAO) by Hyperbaric Oxygenation Therapy (HBO)--Pilot study with 21 patients. *Klin Monatsbl Augenheilkd*. 2002;219:728-734.
4. Dutton GN, Craig G.: Treatment of a retinal embolus by photocoagulation. *Br J Ophthalmol*. 1989;73: 580-581.
5. Mason JO 3rd, Nixon PA, Albert MA Jr.: Trans-luminal Nd:YAG laser embolysis for branch retinal artery occlusion. *Retina*. 2007;27:573-577.
6. Opremcak EM, Benner JD.: Transluminal Nd: YAG laser embolysis for branch retinal artery occlusion. *Retina*. 2002;22:213-216.
7. Yuzurihara D, Iijima H.: Visual outcome in central retinal and branch retinal artery occlusion. *Jpn J Ophthalmol*. 2004;48:490-492.
8. Ros MA, Larry ME, Uram M.: Branch retinal-artery obstruction: a review of 201 eyes. *Ann Ophthalmol*. 1989;21:103-107.
9. Mason JO 3rd, Shah AA, Vail RS, et al.: Branch Retinal Artery Occlusion: Visual Prognosis. *Am J Ophthalmol*. 2008;146:455-457.
10. Lu N, Yang QS, Ma K, et al.: Preliminary report of Nd:YAG embolysis of branch retinal artery occlusion. *Zhongka Yan Ka Zhi*. 2002;42:326-329.
11. Feist RM, Emond TL.: Transluminal Nd: YAG laser embolysis for central retinal artery occlusion. *Retina*. 2005;25:797-799.
12. Opremcak E, Rehmar AJ, Ridenour CD, et al.: Restoration of retinal blood flow via transluminal Nd:YAG embolysis/embolotomy (TYL/E) for central and branch retinal artery occlusion. *Retina*. 2008;28:226-235.