

Aflibercept for Macular Edema Secondary to Branch Retinal Vein Occlusion: Two-Year Results

Ender SIRAKAYA¹, Deniz KILIC¹

ABSTRACT

Purpose: To investigate the two-year visual and anatomical outcomes of patients who had intravitreal aflibercept monotherapy for macular edema due to branch retinal vein occlusion (BRVO).

Methods: Twenty-nine eyes were included in this retrospective cohort study. All eyes were newly diagnosed as BRVO and were treated with intravitreal injections of aflibercept. After three-months loading doses, patients were treated with a single dose of aflibercept if needed. The best-corrected visual acuity (BCVA) and the central macular thickness (CMT) were recorded at each monthly visit.

Results: The mean ages of patients were 61.3±7.6 years. The mean BCVA was 52.2±8.5 letters at baseline, 70.1±11.2 letters at the first year ($p<0.001$), 69.7±12.5 letters at the second year ($p<0.001$). The mean CMT was 555±102 μm at baseline; 285±50 μm at the first year ($p<0.001$), 270±52 μm at the second year ($p<0.001$). In the first year, the mean number of injections was 5.9±1.2 whereas in the second year it was 2.1±0.9.

Conclusion: These long-term real-life results suggest that the intravitreal aflibercept is an effective treatment regimen for eyes with macular edema in BRVO.

Keywords: Aflibercept, branch retinal vein occlusion, macular edema, long-term results.

INTRODUCTION

Retinal vein occlusion is one of the frequently seen retinal vascular diseases following the diabetic retinopathy with a prevalence of approximately four per 1000.¹ The two common subtypes are the central (CRVO) and the branch retinal vein occlusions (BRVO). The occluded vein is the central vein in the (CRVO) whereas one of the branches in the BRVO. Systemic hypertension is the leading cause followed by diabetes mellitus, hyperlipidemia, coagulopathies, systemic inflammatory diseases and drugs.² Once the occlusion occurs, the hemodynamics of the retina is impaired and thus a macular edema is seen.³ The findings of increased vascular endothelial growth factor (VEGF) as well as inflammatory cytokines in the vitreous samples of eyes with BRVO, have led the use of intravitreal anti-VEGF agents and/or steroids in the treatment of macular edema caused by BRVO.⁴

The common used intravitreal anti-VEGF agents for BRVO-related macular edema are Ranibizumab, Bevacizumab and Aflibercept. Aflibercept is a recombinant fusion protein that blocks not only VEGF isoforms, as the other anti-VEGFs do, but also the placental growth factor.^{5,6} The blockage of isoforms of VEGFs is the superiority of Aflibercept to the other anti-VEGFs.⁴ The current literature has shown the two-year efficacy of aflibercept in the treatment of macular edema caused by central retinal vascular occlusions (CRVO).⁷ However, to the best of our knowledge, the long-term results of aflibercept treatment for BRVO-linked macular edema still lack (PubMed Mesh and Google Scholar searched for branch retinal vein occlusions, aflibercept, 2-year results, long-term results, two-year results). For this reason, the aim of this study was to present the two-year results of aflibercept treatment in the macular edema caused by BRVO.

1- MD, Department of Ophthalmology, Kayseri City Training and Research Hospital, Health Science University, Kayseri, Turkey

Received: 15.05.2020

Accepted: 14.07.2020

Ret-Vit 2020; 29: 313-317

DOI:10.37845/ret.vit.2020.29.57

Correspondence Address:

Deniz KILIC

Department of Ophthalmology, Kayseri City Training and Research Hospital, Health Science University, Kayseri, Turkey

Phone: +90 505 920 3928

E-mail: dnz_kilic@hotmail.com

PATIENTS AND METHODS

Study Design

This study was performed in the Department of Ophthalmology, Kayseri City Training and Research Hospital, Health Science University, Kayseri, Turkey. The Research Ethics Committee of Erciyes University (2019/382) approved this retrospective, cohort study. The tenets of the Helsinki Declaration were strictly adhered to by the researchers.

Patient Selection

The medical data of patients who were diagnosed as macular edema secondary to BRVO between April 2015 and April 2019 were reviewed. There were 314 medical records of patients who were diagnosed as BRVO in only eye. The data were excluded if the history of previous treatment or detailed examination were missing (123), if the patients were referred to the other treatments than aflibercept (62) or if the patients were previously treated for BRVO (74). There were 55 treatment-naïve patients who were commenced for only intravitreal aflibercept treatment. However, 29 patients were able to complete the follow-up visits for 2 years. Twenty-one were lost to follow up and five were switched to another treatment regimen. The switch reason was being unable to adhere to monthly visits in three patients who received intravitreal dexamethasone treatment. In the other two patients, the switch reason could not be clarified.

The participants underwent a detailed ophthalmic examination that included best-corrected visual acuity (BCVA) measurement with the letters in early treatment of diabetic retinopathy study (ETDRS) chart, anterior segment examination with slit-lamp bio-microscopy (SL 800, Carl Zeiss Meditec AG, Jena, Germany) and fundus examination of the dilated pupilla.

BRVO Diagnosis, Optical Coherence Tomography (OCT) Measurements

If the patients' clinical findings were indicating a retinal vascular occlusion, they were scheduled for imaging technique, *fundus fluorescein angiography* (FFA). If there was a significant non-ischemic BRVO, the clinicians acquired high-resolution images of six radial scans from the patients' fovea using spectral domain OCT (Heidelberg Engineering, Heidelberg, Germany). The patients were not classified to the localization of the obstructed vein, e.g., first division, macular division. Central macular thickness (CMT) measurements were obtained from the automated calculations of the OCT scans. Finally, the patients who had a BCVA of 30 to 90 letters and a CMT of ≥ 250 μm

were included in the study with a diagnose of macular edema secondary to BRVO.

Intravitreal Aflibercept Injections (IAI)

Once the diagnosis made the patients all informed about the IAI regime by a retina specialist and a written consent was obtained from all patients. Briefly, the patients underwent a *loading dose*, one injection for every 4 weeks up to week 12. Then, the patients were followed up for every consecutive month for at least 100 weeks. Patients had additional IAI in a regimen called *as needed* or *pro re nata* (PRN).

The regimen of PRN IAI was described previously,^{7,8} in which the treatment was repeated if the patients had persistent diffuse retinal edema with a CMT of ≥ 250 μm in the central subfield, or a > 50 μm increase in CMT from the last thickest CMT. Additionally to the anatomical measurements, BCVA was also used as retreatment criteria: A decrease of five or more letters from the last BCVA in conjunction with any increase in CMT, or an increase of five or more letters in BCVA (a clinical finding that the patient could gain more letters).

All the injections were administered in an operating room, under sterile conditions, 4mm behind the corneal limbus in phakic eyes whereas 3.5mm behind in pseudophakic eyes with a 30 Gauge syringe. All the patients were prescribed with moxifloxacin 4x1 for a week. During the intervals of visits, patients were forbidden to use another treatment, such as non-steroidal anti-inflammatory drugs.

Statistical Analysis

Statistical Package for the Social Sciences version 23.0 for Windows (SPSS, Chicago, IL, USA) was used for all the statistical analyses. Numerical data sets were tested for normal distribution with the Shapiro-Wilk test, while categorical variables were analyzed using the chi-square test. To identify the descriptive statistics, 'mean \pm standard deviation', 'median (min-max)' and 'percentage (%)' were used. All data were analyzed statistically by repeated analysis of variance and paired t-test. Pairwise comparisons were conducted with the Bonferroni test. A *p* value of less than 0.05 was considered significant.

RESULTS

Patient Demographics, Baseline BCVA and CMT

There were 29 patients included in this retrospective study with a mean age of 61.3 ± 7.6 (range, 47-74) years. The prevalence of male patients was 48% (14 male - 15 female) whereas the percentages of the laterality of the affected

Table 1. Demographic characteristics and baseline measurements.

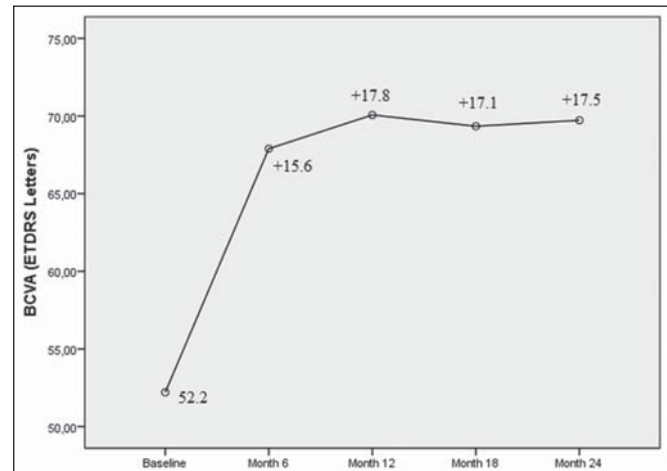
Mean ages years±SD (min-max)	61.3±7.6 (47-74)
Male to female ratio	14/15
Mean BCVA letters±SD (min-max)	52.2±8.5 (33-68)
Mean CMT µm±SD (min-max)	555±102 (407-796)
Mean IAI in the first year number±SD (min-max)	5.9±1.2 (4-9)
Mean IAI in the second year number±SD (min-max)	2.1±0.9 (0-4)

SD, standard deviation; min-max, minimum-maximum; BCVA, best-corrected visual acuity; CMT, central macular thickness; IAI, intravitreal aflibercept injection.

eyes were similar (13 - 45% right eyes; 16 - 55% left eyes). The mean BCVA was 52.2±8.5 (range, 33-68) letters and the mean CMT was found to be 555±102 (range, 407-796) µm (Table 1).

Change in BCVA and CMT, Number of Injections

The mean BCVA was 70.1±11.2 (range, 43-83) letters at the first year and 69.7±12.5 (range, 35-82) letters at the second year. The change in BCVA from baseline to 12th month was significant (+17.9 letters $p < 0.001$); besides,

**Figure 1.** Mean change in best-corrected visual acuity (BCVA) in letters of early treatment of diabetic retinopathy study chart (ETDRS).

the BCVA did not significantly change through the second year. The mean change in BCVA was shown in Fig. 1. The percentage of the patients who gained more than 10 letters was 86% whereas it was 83% at the end of the study (Table 2).

The mean CMT was significantly decreased to 285±50 (range, 151-363) µm, at first year. The change in CMT from baseline to first year was significant (-270.50 µm and $p < 0.001$), whereas the reduction at the second year was not significant (-14.4 µm and $p = 0.914$). Fig. 2 depicts the change in CMT during the 2 years.

In the first year, patients received an average of 5.9±1.2 (range, 4-9) injections and it was decreased to 2.1±0.9 (range, 0-4) in the second year.

Table 2. Details of the BCVA increase.

	VA gain letters Mean±SD (95% CI)	Patients gained > 0 letters (percentage)	Patients gained ≥ 5 letters (percentage)	Patients gained ≥ 10 letters (percentage)	Patients gained ≥ 15 letters (percentage)
At 3 Months	13.3±7.3 (10.6 - 15.9)	27/29 (93%)	26/29 (%90)	18/29 (62%)	11/29 (%38)
At 6 Months	15.7±7.8 (12.9 - 18.6)	28/29 (%97)	27/29 (%93)	23/29 (%79)	13/29 (%45)
At 12 Months	17.9±9.6 (14.2 - 21.1)	28/29 (%97)	26/29 (%90)	25/29 (%86)	18/29 (%62)
At 24 Months	17.5±11.0 (13.0 - 21.1)	26/29 (%90)	26/29 (%90)	24/29 (%83)	18/29 (%62)

VA; Visual acuity

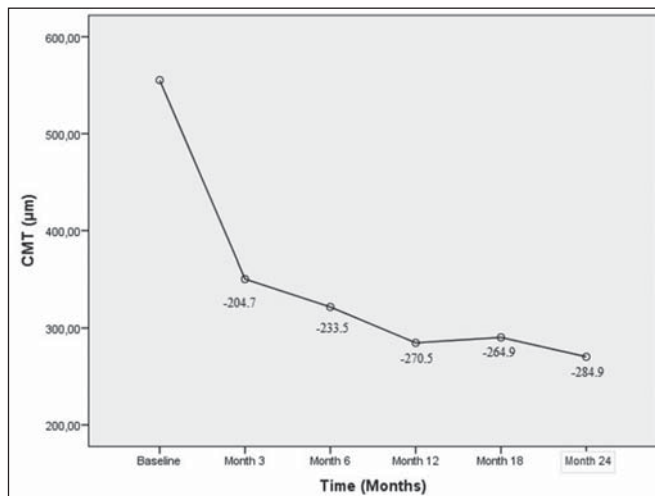


Figure 2. Mean change in central macular thickness (CMT).

DISCUSSION

The present study is unique study demonstrating the long term results of aflibercept treatment in macular edema secondary to BRVO. The results showed a significant increase in BCVA in the first year and the increase was permanent in the second year. Besides, the CMT was significantly decreased in the first year and the reduction maintained to the end of the study, with a slightly decrease in the mean injection numbers (2.1) in the second year.

In published epidemiological studies, older age was found to be a significant risk factor in the development of BRVO, while gender was found to have no effect.¹ In this present study, the mean age was older than 60 years, which was similar to the previous studies.^{9,10} Furthermore, this study revealed that both sexes and both eyes were affected in a similar ratio, parallel to the findings with the previously population-based studies.¹ This might be the result of that the more a person gets older the more he/she likely to have arteriosclerosis and age-related vascular (e.g., systemic hypertension) diseases. In a recent study,¹¹ older age was also found to be a poor prognostic factor for the response to the treatment with IAI whereas the present study was not focused on the prognostic factors.

The impaired visual acuity constitutes the main clinical complaints of the patients with BRVO especially when the macular edema develops. The current literature proved a significant improvement in BCVA with the use of aflibercept in the macular edema secondary to BRVO. In a 52-week multinational, phase III study, Clark et al.¹² found that the mean change in BCVA was 17.1 letters. In another study by Kaya et al.⁵, the aflibercept was found to be an effective agent to provide a significant increase in BCVA at the end of the first year. The present study demonstrated similar results that the BCVA significantly increased in

the first year with a change of 17.9 letters. Besides, the percentage of the patients gained ≥ 10 letters were similar with the Clark et al.'s study,¹² where they found a 80.2%. In addition to the current literature, this study provided new data showing that BCVA was improved in the first year and was maintained steady in the second year.

In this current study, there was a significant reduction in CMT shown by OCT at the first year. However, after twelve months, there were no significant changes in the thickness. The 12 months-results were similar with the Clark et al.'s study;¹² in which the mean reduction in CMT was $-283 \mu\text{m}$. In another study by Pichi et al.¹³, the 12 months-efficacy of aflibercept and ranibizumab in macular edema secondary to non-ischemic BRVO was evaluated. The authors concluded that in both groups the mean CMT was significantly reduced. The mean decrease in aflibercept treatment group (498 ± 46 to $204 \pm 23 \mu\text{m}$) was in consistent with this study. It is suggested that the maximum gain in both BCVA and reduction in CMT could be achieved with in the first year. Although the improvement in the second year seems to be insignificant, the patients should strictly adhere to their visits, as they can need PRN injection. In this study, monthly visits required for all of the patients, whereas the numbers of IAI were reduced in the second year to approximately two injections per year. Based on these results, the authors assume that the patients' follow-up visits may be reduced to once every two months within the second year.

The retrospective design, the small number of patients and the absence of other treatment and/or sham injection groups to compare were the main limitations of this study. However, the scope of this study was to report the 2-year results of the IAI, not to compare the different treatment strategies. The other limitation was not to record the adverse events, which was also not the aim of the study. Besides the limitations, this study has strength that it was the first study that presented long-term and real-life results of IAI treatment for BRVO related macular edema.

CONCLUSION

In summary, the results of this study revealed that the IAI for macular edema secondary to BRVO is efficient to improve the BCVA and to reduce the CMT. The efficacy reaches in the first year of the therapy and maintains to the end of the second year.

ACKNOWLEDGEMENTS

Contributions

ES and DK conceived the study and its design, acquired the data, drafted the article, and critically revised the paper for important intellectual content.

All authors read and approved the final manuscript.

Declaration of interest

There is no conflict of interest.

Funding

No funding received

REFERENCES

1. Rogers S, McIntosh RL, Cheung N, et al. The prevalence of retinal vein occlusion: pooled data from population studies from the United States, Europe, Asia, and Australia. *Ophthalmology*. 2010;117:313-9.e1. doi:10.1016/j.ophtha.2009.07.017
2. Lashay A, Riazi-Esfahani H, Mirghorbani M, et al. Intravitreal Medications for Retinal Vein Occlusion: Systematic Review and Meta-analysis. *J Ophthalmic Vis Res*. 2019;14:336-66. doi:10.18502/jovr.v14i3.4791
3. Babiuch AS, Han M, Conti FF, et al. Association of Disorganization of Retinal Inner Layers With Visual Acuity Response to Anti-Vascular Endothelial Growth Factor Therapy for Macular Edema Secondary to Retinal Vein Occlusion. *JAMA Ophthalmol*. 2019;137:38-46. doi:10.1001/jamaophthalmol.2018.4484
4. Ho M, Liu DTL, Lam DSC, et al. Retinal Vein Occlusions, From Basics to The Latest Treatment. *Retina*. 2016;36:432-48. doi:10.1097/IAE.0000000000000843
5. Kaya F, Kocak I, Aydin A, et al. Comparison of Intravitreal Aflibercept and Ranibizumab for Macular Edema Secondary to Branch Retinal Vein Occlusion. *J RetVit*. 2018;27:1-10.
6. Hoy SM. Aflibercept: A Review in Macular Oedema Secondary to Branch Retinal Vein Occlusion. *Drugs Aging*. 2017;34:393-400. doi:10.1007/s40266-017-0458-6
7. Heier JS, Clark WL, Boyer DS, et al. Intravitreal aflibercept injection for macular edema due to central retinal vein occlusion: two-year results from the COPERNICUS study. *Ophthalmology*. 2014;121:1414-1420.e1. doi:10.1016/j.ophtha.2014.01.027
8. Brown DM, Heier JS, Clark WL, et al. Intravitreal aflibercept injection for macular edema secondary to central retinal vein occlusion: 1-year results from the phase 3 COPERNICUS study. *Am J Ophthalmol*. 2013;155:429-37.e7. doi:10.1016/j.ajo.2012.09.026
9. Spooner K, Hong T, Fraser-Bell S, et al. Current Outcomes of Anti-VEGF Therapy in the Treatment of Macular Oedema Secondary to Branch Retinal Vein Occlusions: A Meta-Analysis. *Ophthalmol J Int d'ophtalmologie Int J Ophthalmol Zeitschrift fur Augenheilkd*. 2019;242:163-77. doi:10.1159/000497492
10. Holz FG, Roeder J, Ogura Y, et al. VEGF Trap-Eye for macular oedema secondary to central retinal vein occlusion: 6-month results of the phase III GALILEO study. *Br J Ophthalmol*. 2013;97:278-84. doi:10.1136/bjophthalmol-2012-301504
11. Sirakaya E, Küçük B, Ağadayı A. Aflibercept Treatment for Macular Edema following Branch Retinal Vein Occlusion: Age-Based Responses. *Ophthalmologica*. 2020;243:94-101. doi:10.1159/000502042
12. Clark WL, Boyer DS, Heier JS, et al. Intravitreal Aflibercept for Macular Edema Following Branch Retinal Vein Occlusion: 52-Week Results of the VIBRANT Study. *Ophthalmology*. 2016;123:330-6. doi:10.1016/j.ophtha.2015.09.035
13. Pichi F, Elbarky AM, Elhamaky TR. Outcome of "treat and monitor" regimen of aflibercept and ranibizumab in macular edema secondary to non-ischemic branch retinal vein occlusion. *Int Ophthalmol*. 2019;39:145-53. doi:10.1007/s10792-017-0798-6