


# New Insights into Persistent Subretinal Fluid After Pars Plana Vitrectomy for Rhegmatogenous Retinal Detachment

Noureldin Hussein Hashem<sup>1</sup>, Weam Mohamed Ebeid<sup>1</sup> 

## ABSTRACT

**Purpose:** To illustrate different scenarios of minimal persistent subretinal fluid (PSRF) after pars plana vitrectomy (PPV) for rhegmatogenous retinal detachment (RRD)

**Methods:** In our retrospective case series we recorded age, Best-corrected visual acuity (BCVA), spherical equivalent, fundus examination pre- and post-operatively as well as serial Optical coherence tomography (OCT) to follow up PSRF.

**Results:** All eyes showed gradual decrease in PSRF for up to one year in some cases, as demonstrated by OCT. BCVA improved significantly at total subsidence of the PSRF compared to early postoperative BCVA.

**Conclusion:** PSRF can delay visual recovery after PPV for RRD for up to one year postoperatively but still resorb spontaneously even in high myopes, upper retinal tear, lower PSRF or even following removal of Silicon oil tamponade. It is thus plausible to avoid hazardous early surgical drainage with close monitoring to exclude open retinal breaks or evident traction that necessitate drainage.

**Keywords:** Optical coherence tomography; Pars Plana Vitrectomy; Persistent Subretinal Fluid; Posterior retinotomy; Rhegmatogenous Retinal Detachment; Subretinal Fluid drainage.

## INTRODUCTION

Pars plana vitrectomy (PPV) has become the gold standard operation for rhegmatogenous retinal detachment (RRD). The occurrence of Persistent subretinal fluid (PSRF) is not uncommon in eyes treated with vitrectomy, with the incidence ranging between 0% and 15% at 4 to 6 weeks after surgery.<sup>1</sup>

In many cases of RRD, subretinal fluid (SRF) absorption proceeds very rapidly when the retinal breaks are closed, even without drainage of fluid, as in pneumatic retinopexy. However, it is still unclear why small fluid remnants take months to resorb in certain cases.<sup>2</sup>

Earlier reports have suggested that factors which facilitate SRF absorption, include gradients of the oncotic and hydrostatic pressure, along with an active retinal pigment epithelial (RPE) pump.<sup>3</sup>

Several hypotheses have been suggested for delayed

absorption of SRF. Subclinical RPE dysfunction is advocated as a key factor. Additionally, chronic detachment is usually associated with viscous SRF, which may be an important cause in the persistence of shallow SRF after retinal reattachment.<sup>4,5</sup>

Optical coherence tomography (OCT) can be used to diagnose, document, and follow up PSRF after RRD surgery. Standard OCT B-scan images may show PSRF for several months after successful surgery, it can even depict minimal SRF, when the retina appears fully attached on fundus examination.<sup>6,7</sup>

In this study we aimed to discuss the different scenarios of some of our cases with minimal nonprogressive PSRF after PPV for RRD, highlighting the variable clinical course and the final visual outcome. Our follow up continued till complete resorption of the PSRF that extended for up to one year in some cases.

1- MD, Ain Shams University, Faculty of Medicine, Ophthalmology Department, Cairo, Mısır

2- MD, Ain shams university, ophthalmology, Cairo, Mısır

Received: 18.06.2021

Accepted: 06.07.2021

*Ret-Vit 2021; 368-374*

DOI: 10.37845/ret.vit.2021.30.63

**Correspondence Address:**

Weam Mohamed Ebeid  
Ain Shams University, Faculty of Medicine, Ophthalmology Department,  
Cairo, Mısır

**Phone:** +20 100 378 5838

**E-mail:** weam.ebeid@med.asu.edu.eg

## METHODS

This is a retrospective case series that enrolled data of patients with macula-off RRD who underwent PPV surgery at Ain Shams University hospitals and Al-Mashreq eye center, Cairo, Egypt. Cases included were those who showed postoperative minimal, nonprogressive PSRF. All the cases had been followed up in the time interval between November 2018 and March 2020. The study adhered to the Tenets of the Declaration of Helsinki, with informed consents signed by all participants. The study protocol was approved by the Ethical Committee of the faculty of medicine, Ain Shams University.

Patients' files were searched to obtain the relevant data in preoperative and postoperative visits till subsidence of PSRF (up to 12 months). Data including detailed ocular and medical history, as well as operative details like the used intraoperative tamponade and SRF drainage method were all recorded. Clinical characteristics encompassed age, gender, best corrected visual acuity (BCVA) measured using Snellen chart preoperatively and in serial follow up visits, intraocular pressure (IOP), and spherical equivalent (autorefractor; ARK1, Nidek, Gamagori, Japan). Patients also had slit-lamp examination, and dilated fundus examination with state of proliferative vitreoretinopathy (PVR), and site of the SRF documented in preoperative and in all follow up visits.

In addition, serial spectral domain OCT RTVue-XR Avanti (Optovue Inc, Fremont, California, USA) was performed at post-operative visits to document and follow up the SRF.

### Surgical technique

All cases underwent 23 G transconjunctival PPV by the same vitreoretinal surgeon (NH) under local or general

anesthesia using the Constellation system (Alcon Laboratories, Fort Worth, TX, USA). All procedures were performed under wide-angle visualization applying a 3 port trocar cannula system. Core vitrectomy then peripheral vitreous cutting were done after scleral indentation. Scleral buckling was needed only in one case (case 9). Subretinal fluid was drained following fluid-air exchange, through the existing retinal break or an intentionally created retinotomy, with or without injection of perfluorocarbon (PFC). Endolaserphotocoagulation was applied to retinal breaks, transscleral cryopexy was performed only in the case that needed adjuvant buckle (case 9). At the end of the procedures, either 20% Sulfur hexafluoride (SF6) gas or silicone oil (SO) 2000Cs was injected as a tamponade agent.

Exclusion criteria included history of any previous ocular trauma, significant media opacity, uveitis, or giant retinal tear. We also excluded cases with combined tractional rhegmatogenous detachment, or significant preretinal fibrosis.

## RESULTS

The study included twelve eyes of 12 RRD patients who underwent PPV and demonstrated postoperative minimal nonprogressive PSRF. All cases were followed up till complete resolution of PSRF, with up to one-year duration of follow up. The participants' age range was 9-65 years, with a mean of  $42.35 \pm 15.12$  years. Detailed patient data are demonstrated in Table 1. For each patient, measured visual acuity in all follow up visits are shown in Table 2.

In two of our 12 eyes (16%) SRF persisted for 12 months, and in one patient it persisted for 6 months. In the remaining

**Table 1:** Patients characteristics.

Patient number	Age, years	Sex, F/M	Medical history	Ocular history	Spherical equivalent, diopters	Duration of detachment, days	Site of the break	Preoperative Fluid	Proliferative vitreoretinopathy	Tamponade	Site of persistent fluid	Time of resolution of SRF	Silicone oil removal, months	Drainage method
1	65	M	DM HTN	Pseudophake	0.50	5d	Lower	Central	A	GAS	Central	6M	-	Main break
2	58	F	-	Pseudophake	-10.5	8d	UP+ central	Up+ central	A	SOI	Up+ central	12M	3m	Main break
3	45	M	HTN	LASIK 5Y	0.75	1d	UP+ lower	Up+ lower	C	SOI	Lower+ central	12M	7m	Retinotomy+ PFC

**DM:** diabetes mellitus, **HTN:** systemic hypertension, **SRF:** subretinal fluid, **d:** day, **m:** month, **F/M:** female/male, **PFC:** perfluorocarbon, **SOI:** silicon oil injection.

**Table 2:** Best corrected visual acuity (BCVA) in follow up visits.

Patient number	Preoperative BCVA	BCVA 1M	BCVA 3M	BCVA 6M	BCVA 12M
1	HM	20/50	20/32	20/25	-
2	HM	20/63	20/63	20/50	20/32
3	20/400	20/200	20/200	20/63	20/63

M: month, HM: hand motion.

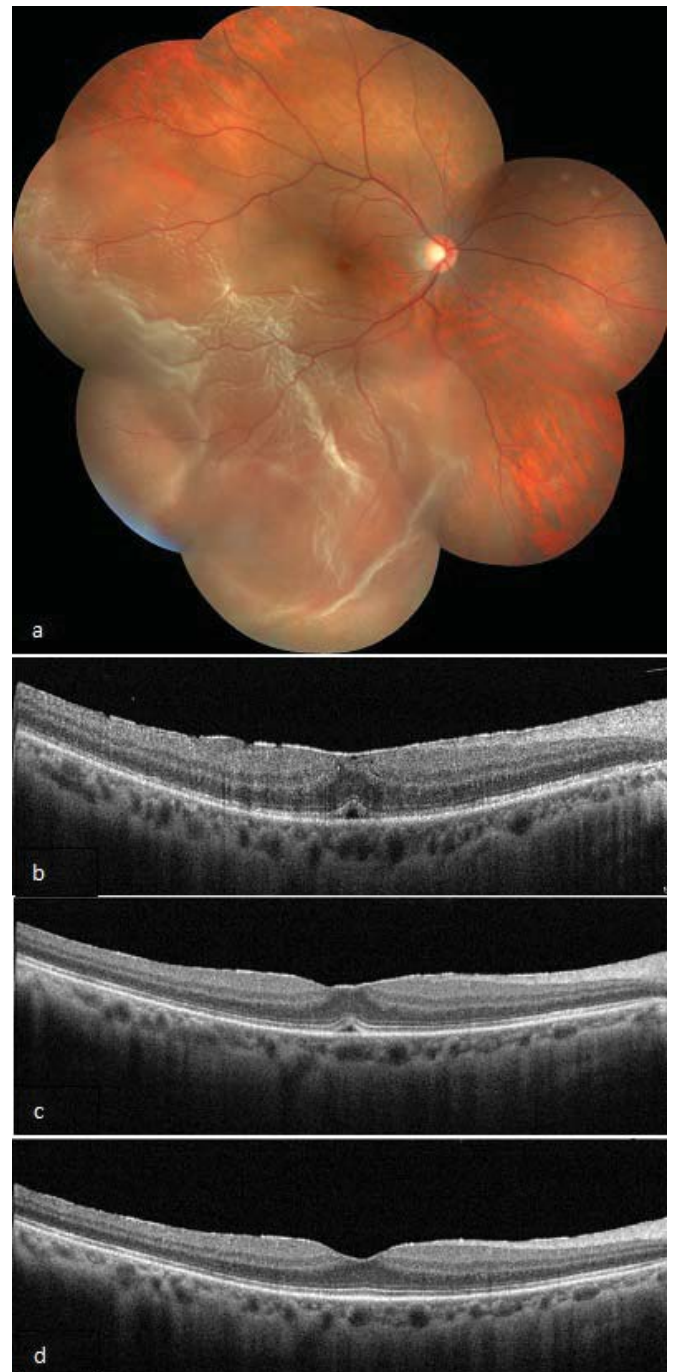
9 cases PSRF resolved within 48 hours, and thus, they were not furtherly analyzed.

All the eyes encompassed in the study showed gradual decrease in SRF in the subfoveal area throughout the follow up period as demonstrated by serial OCT images. Visual acuity improved significantly in most cases at last follow-up (total subsidence of the PSRF) when compared either to preoperative VA or VA in the early postoperative period in which PSRF was still present.

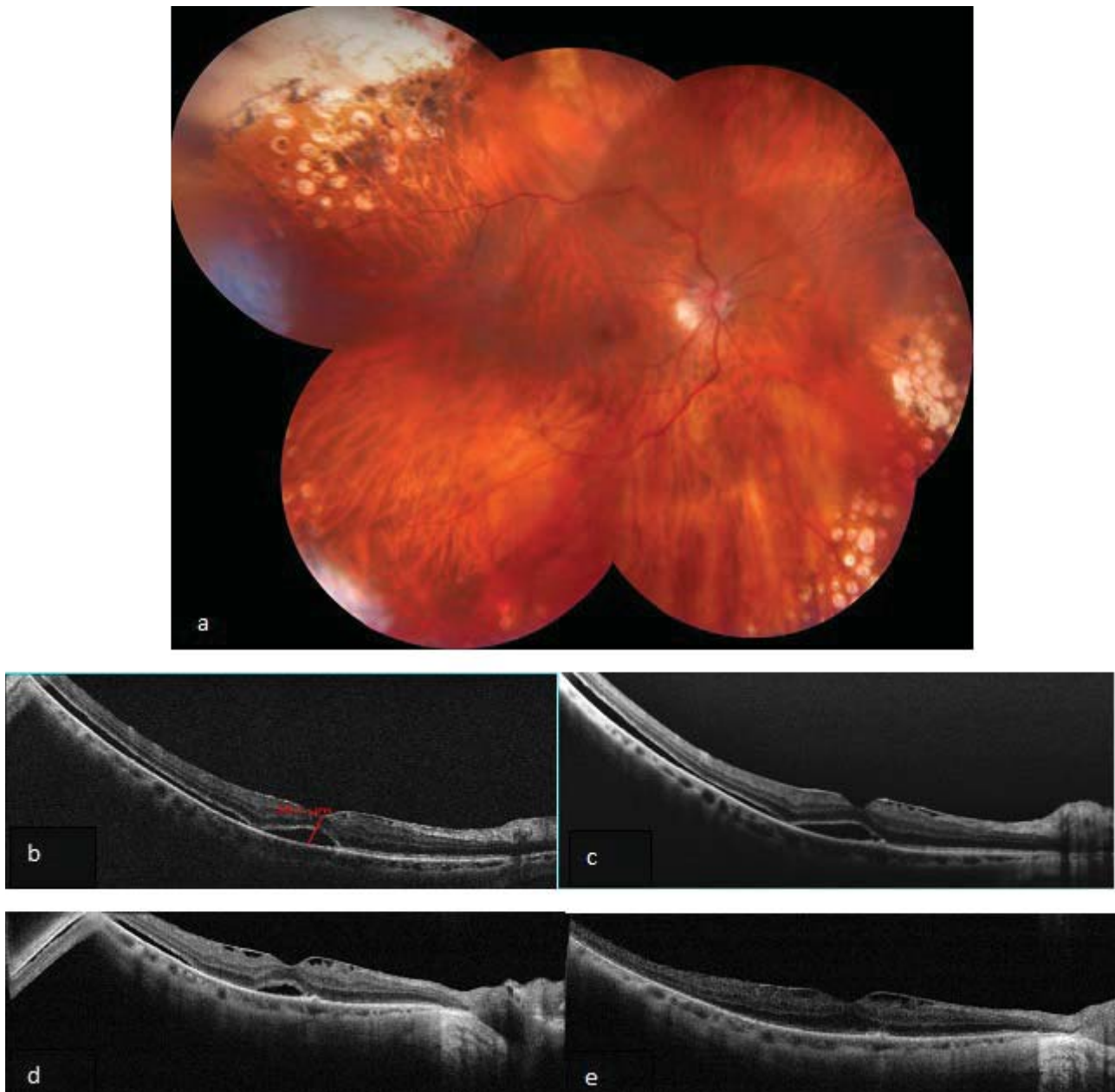Our first case was a 65-year-old diabetic hypertensive male patient who presented with right macula off RRD with a temporal break. PPV surgery with SF6 gas injection was performed. Central subfoveal PSRF persisted for 6 months postoperatively. His BCVA improved from HM preoperatively to 20/50 one month postoperatively, gradually improving by 3 lines to reach 20/25 on resolution of all the fluid 6 month postoperatively. OCT of the right eye illustrates the gradual fluid resorption. (see Figure1, that demonstrates the Fundus and serial follow up Optical coherence tomography of Case no 1.)

Case two was a 58-year-old myopic female patient who presented with an upper retinal break resulting in upper and central RRD. PPV was done and SRF was drained via a peripheral retinotomy with SO injection. Postoperatively PSRF was seen under upper and central retina. SO was removed 3 months later despite the presence of PSRF. However, the surgeon’s decision during SO removal was not to attempt draining the PSRF to avoid unnecessary retinotomy since the break was already well sealed and no retinal traction was seen on meticulous retinal examination. Resorption of the PSRF was not completed till 12 months after PPV, nine months following SOR. Her right BCVA improved gradually from 20/63 in the early postoperative period to reach 20/32 at 12 months upon total subsidence of the PSRF. OCT images clearly demonstrates the gradual resolution of the fluid. (see Figure 2, that demonstrates the Fundus and serial follow up Optical coherence tomography of Case no 2.)

Case no three was a 45-year-old hypertensive male who presented with chronic right lower RD that was only discovered when the fluid extended under the macula and



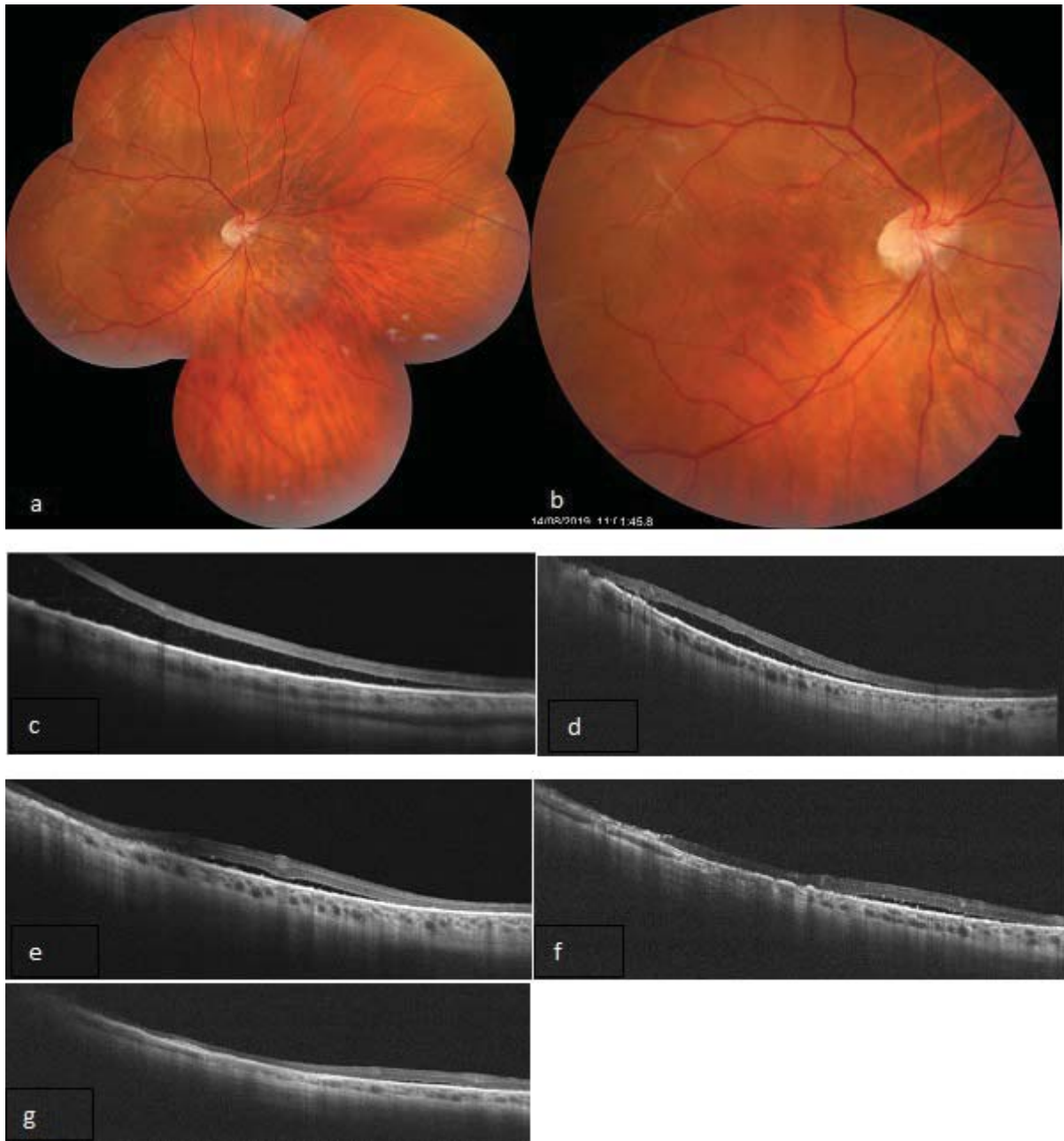
**Figure 1:** Fundus and serial follow up Optical coherence tomography of Case no 1. a: Preoperative color fundus picture showing lower central rhegmatogenous retinal detachment. b: OCT 1month after pars plana vitrectomy (PPV) demonstrating minimal subfoveal subretinal fluid (SRF). c: OCT 3months after PPV showing partial absorption of the fluid. d: Complete absorption of the SRF 6 months after PPV.



**Figure 2:** Fundus and serial follow up Optical coherence tomography of Case no 2. *a:* Preoperative color fundus picture showing upper central rhegmatogenous retinal detachment, with peripheral retinal degenerations and laser marks in a high myopic fundus. *b:* OCT 1 month after pars plana vitrectomy (PPV) demonstrating minimal subfoveal and upper subretinal fluid (SRF) with thin epiretinal membrane exerting minimal insignificant tangential traction. *c:* OCT 2 month after PPV almost demonstrating the same picture. *d:* OCT after SO removal 4 months after PPV showing persistent SRF. *e:* complete absorption of the SRF 12 months after PPV.

he presented to us with 2 days history of drop of vision where examination revealed macula off RRD with lower demarcation line involving most of the retina with PVR C and short atrophic retina. We performed PPV and SO injection with central retinotomy for removal of subretinal band and peripheral wide laser barrage. There was no need for either scleral buckle or peripheral retinectomy. Regular follow up both clinically and by OCT was done till complete absorption of lower PSRF that occurred 7

months later. However, central fluid in the form of fluid pockets of was not totally resorbed till 12 months after PPV. His right visual acuity was 20/200 postoperatively and after resolution of PSRF it only improved to 20/63 owing to the atrophic central retina. OCT of the right eye revealed the lower PSRF resolution. (see Figure 3, that demonstrates the Fundus and serial follow up Optical coherence tomography of Case no 3).



**Figure 3:** Fundus and serial follow up Optical coherence tomography of Case no 3. a,b: Preoperative color fundus picture showing subtotal rhegmatogenous retinal detachment, with upper temporal subretinal bands. c-g: serial follow up OCT after pars plana vitrectomy (PPV) demonstrating the gradual absorption of the lower subretinal fluid at 1,3,6,9, and 12 months after PPV respectively.

## DISCUSSION

In this case series we aimed to illustrate different scenarios of minimal, nonprogressive PSRF in cases of RRD treated with PPV; in which follow up continued till complete resorption of the PSRF that extended for up to one year in some cases.

Complete drainage of all SRF during PPV for RRD usually requires either the creation of a posterior retinotomy and/or the use of heavy PFC liquids. Hazards related to posterior retinotomy include further retinal damage, and prompting

fibrous retinal proliferation, while the use of PFC carries the hazard of intraocular retention with consequent retinal toxicity. In order to avoid these complications, drainage of SRF is preferably done through a single retinotomy with minimal central fluid left over rather than doing multiple retinotomies or using PFC to drain the fluid completely. Thus, PSRF in early postoperative period is a very pervasive.<sup>8,9</sup>

Persistent SRF can delay or even compromise visual recovery following vitrectomy or scleral buckling surgery

for RRD. Both the fluid composition and the rate of fluid absorption mutually contribute to the pathogenesis of SRF.<sup>10</sup>

The speedy retinal reattachment seen in case of pneumatic retinopathy and in scleral buckling demonstrated that SRF could be absorbed spontaneously without SRF drainage when the principal source for fluid was sealed. The active fluid transport from subretinal space into choroidal circulation by RPE expedites resolution of SRF after the closure of retinal breaks.<sup>8,11</sup>

All our cases have presented to the vitreoretinal surgeon and undergone PPV within less than 8 days of their first symptom. Thus, the presence of thick viscid fluid; that is commonly seen in cases of chronic RRD, was not the likely cause of the PSRF except for one case.

The use of tamponading material whether SF<sub>6</sub> gas or SOI does not seem to influence the absorption of the PSRF. In addition, the removal of the SO did not affect the course of fluid absorption as in one of our patients (case 2) we removed SO postoperatively without PSRF drainage and gradual resorption of SRF continued to occur after SO removal and was completed 12 months after their primary detachment repair. Thus, we spared the patient an unnecessary retinotomy with its associated complications since eventually the PSRF resorbed spontaneously.

One of the cases with delayed absorption of PSRF (12 months postoperatively) was a high myope with a spherical equivalent of -10.50 diopters. This seems reasonable since it is well known that high myopes have unhealthy RPE,<sup>12</sup> thus less efficient pump action resulting in more delayed fluid absorption. However, other emmetropic patients included in this study demonstrated a similar delay in SRF absorption, implying either that weak RPE function is not limited to high myopes or that other factors might play an equivalent role in the pathogenesis of PSRF.

Up to our knowledge this is the first study to report PSRF in peculiar conditions of superior break or lower persistent fluid. In accord with our findings, prior reports studying PSRF after RRD repair have reported subsidence of the fluid in the majority of their patients within one month postoperatively.<sup>1,8</sup> and up to a year after surgery in few studies.<sup>13</sup> Those studies highlighted that, in most cases PSRF absorb spontaneously with no adverse sequelae.

Limitations of our study include the small sample size, and the retrospective nature. Further randomized longitudinal studies involving a larger cohort are warranted to further emphasize our hypothesis.

In conclusion, Persistent subretinal fluid may ensue even after successful PPV for RRD and can delay visual recovery. Resorption of PSRF may be delayed for up to one year postoperatively but still occurs spontaneously even in high myopes, upper retinal tear, lower PSRF or even after removal of SO tamponade. It is thus plausible to avoid surgical drainage that involves exposing the patient to the hazards associated with retinotomy or retinectomy in such cases. Meanwhile, close follow up with good examination is mandatory to ensure there are no open retinal breaks or evident retinal traction that necessitate surgical drainage of PSRF.

## REFERENCES

1. Benson SE, Schlottmann PG, Bunce C, et al. Optical coherence tomography analysis of the macula after vitrectomy surgery for retinal detachment. *Ophthalmology* 2006; 113:1179e1183.
2. Al Rashaed S. Unusual presentation of residual subretinal fluid composition after surgery for acute rhegmatogenous retinal detachment. *Clinical Ophthalmology* 2013; 7:1069–1072.
3. Veckeneer M, Derycke L, Lindstedt EW, et al. Persistent subretinal fluid after surgery for rhegmatogenous retinal detachment: hypothesis and review. *Graefes Arch Clin Exp Ophthalmol* 2012; 250:795–802.
4. Oellers P, Elliott D. Overloaded Dysfunctional RPE Leads to Delayed Absorption of Subretinal Fluid After Retinal Detachment Repair. *Ophthalmic Surgery, Lasers and Imaging Retina* 2017; 48(10):852-855.
5. Colucciello M. Serial “en face” optical coherence tomography imaging of slowly resorbing subretinal fluid after pneumatic retinopathy. *Retinal cases & brief reports* 2016; 10:286–288.
6. Kaga T, Fonseca RA, Dantas MA, et al. Optical coherence tomography of bleb-like subretinal lesions after retinal reattachment surgery. *Am J Ophthalmol* 2001; 132:120–121.
7. Baba T, Hirose A, Moriyama M, Mochizuki M. Tomographic image and visual recovery of acute macula-off rhegmatogenous retinal detachments. *Graefes Arch Clin Exp Ophthalmol* 2004; 242:576–581.
8. Chen X, Zhang Y, Yan Y, et al. Complete subretinal fluid drainage is not necessary during vitrectomy surgery for macula-off rhegmatogenous retinal detachment with peripheral breaks: A Prospective, Nonrandomized Comparative Interventional Study. *Retina* 2017; 37(3):487-93.
9. Tewari A, Elliott D, Singh CN, et al. Changes in retinal sensitivity from retained subretinal perfluorocarbon liquid. *Retina* 2009; 29:248–250.
10. Chantarasorn Y, Oellers P, Elliott D. Choroidal Thickness Is Associated with Delayed Subretinal Fluid Absorption

- after Rhegmatogenous Retinal Detachment Surgery. *Ophthalmology Retina* 2019; 3:947-955.
11. Sasoh M. The frequency of subretinal fluid drainage and the reattachment rate in retinal detachment surgery. *Retina* 1992; 12:113–117.
  12. Silva R. Myopic Maculopathy: A Review. *Ophthalmologica* 2012; 228:197-213.
  13. Tee JJ, Veckeneer M, Laidlaw DA. Persistent subfoveal fluid following retinal detachment surgery: an SD-OCT guided study on the incidence, aetiological associations, and natural history. *Eye* 2016; 30(3):481-7.