

# Multimodal Imaging in Optic Disc Melanocytoma with Co-Existing Unilateral High Myopia

Selda Çelik Dülger<sup>1</sup>, Büşra Dilara Yıldırım Erdal<sup>1</sup>, Mehmet Yasin Teke<sup>2</sup>

## ABSTRACT

Melanocytoma is generally unilateral, dense pigmented, dark brown to black lesion of uveal tract with the rare potential malignant transformation. It is mostly located entirely or partly in the optic disc. Various ocular associations have been reported in the literature, such as optic disc hypoplasia, retinitis pigmentosa, congenital hypertrophy of the retina pigment epithelium. In this report, we presented a case with unilateral pathologic myopia accompanying optic disc melanocytoma. This is the first reported case of unilateral pathologic myopia coexistent with optic disc melanocytoma to the best of our knowledge.

**Keywords:** Pathologic myopia, optic disc melanocytoma, optic disc, optic nerve, retina.

## INTRODUCTION

Optic disc melanocytoma was first described by Zimmerman. (Zimmerman LE 1962) The reason for this terminology is that melanocyte cells in the uveal tract of patients with ocular melanosis are similar to the tumor cells in the melanocytoma.<sup>1</sup> Although it is named as melanocytoma in the literature, it is a benign tumor with good prognosis. Melanocytomas are generally unilateral, rare and dense pigmented congenital hamartomas of uveal tract with the rare potential malignant transformation. Approximately 1-2% of malignant transformation has been reported.<sup>2</sup> It most often occurs in the choroid and is less frequent in the anterior uvea.<sup>2</sup> It is mostly detected in the fifth decade and predominantly in women.<sup>2</sup> Pathologic myopia is a type of myopia with a thinning of the retina, choroid and sclera due to mechanical stress caused by progressive antero-posterior elongation.<sup>3</sup> The prevalence of degenerative myopia was found to be 0.9%-3.1% in the literature.<sup>3</sup> Among these, unilateral cases are much less common.

In this report, we present an interesting case with unilateral pathologic myopia in her right eye and optic nerve head melanocytoma in her left eye.

## Case Report

A 13 year-old-female presented to our clinic with a complaint of blurred vision in the right eye (RE) and dark spot in vision of the left eye (LE). On ophthalmic examination, best corrected visual acuity (BCVA) was counting finger from 50 cm in the RE, 20/20 in the LE. Anterior segment examination with slit lamp revealed grade 1 nuclear sclerosis in both eyes. At her first fundus examination, there was tilted disc, peripapillary atrophy and posterior staphyloma in the RE. Choroidal vessels were discernible in the fovea because of thinned retina with diffuse chorioretinal atrophy. Dark pigmented lesion extending over the inferior margin of the optic disc to involve the adjacent sensory retina was observed in the LE. (Figure 1a-b) It was recognized that she had been followed in the retina department for ten years. When compared with patients's previous fundus photography, there was no change in the diameter and color of the melanocytoma. Optical coherence tomography (OCT) section passing through the melanocytoma displayed hyperreflective elevated lesion under the nerve fiber layer with shadowing effect. (Figure 2a) In B-scan ultrasonography, there was an excavation caused by posterior staphyloma in the RE. Melanocytoma was observed as hyperechoic lesion on the

1- MD, Ankara Etlik City Hospital, Ankara, Türkiye

2- Prof., Ankara Etlik City Hospital, Ankara, Türkiye

Received: 17.01.2023

Accepted: 10.03.2023

*J Ret-Vit* 2023; 32:158-161

DOI:10.37845/ret.vit.2023.32.27

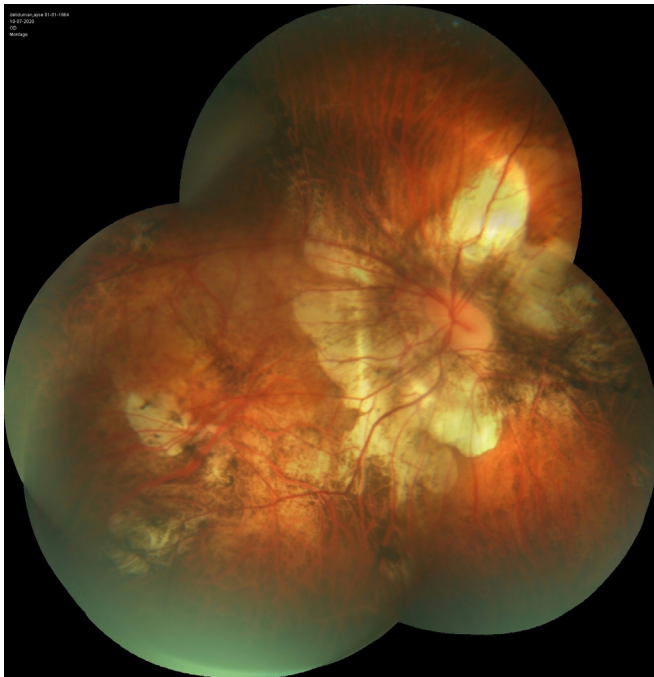
**Correspondence Address:**

Selda Celik Dulger

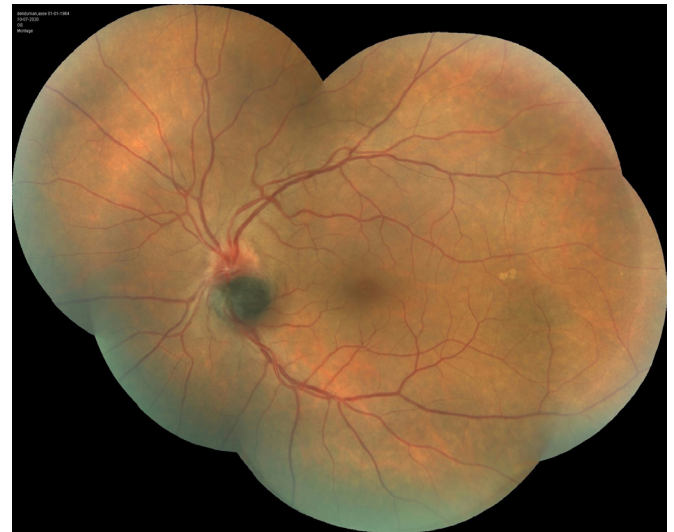Ankara Etlik City Hospital, Halil Sezai Erkut Cd. 06170 Yenimahalle  
Ankara, Türkiye

**Phone:** +90 312 797 0000

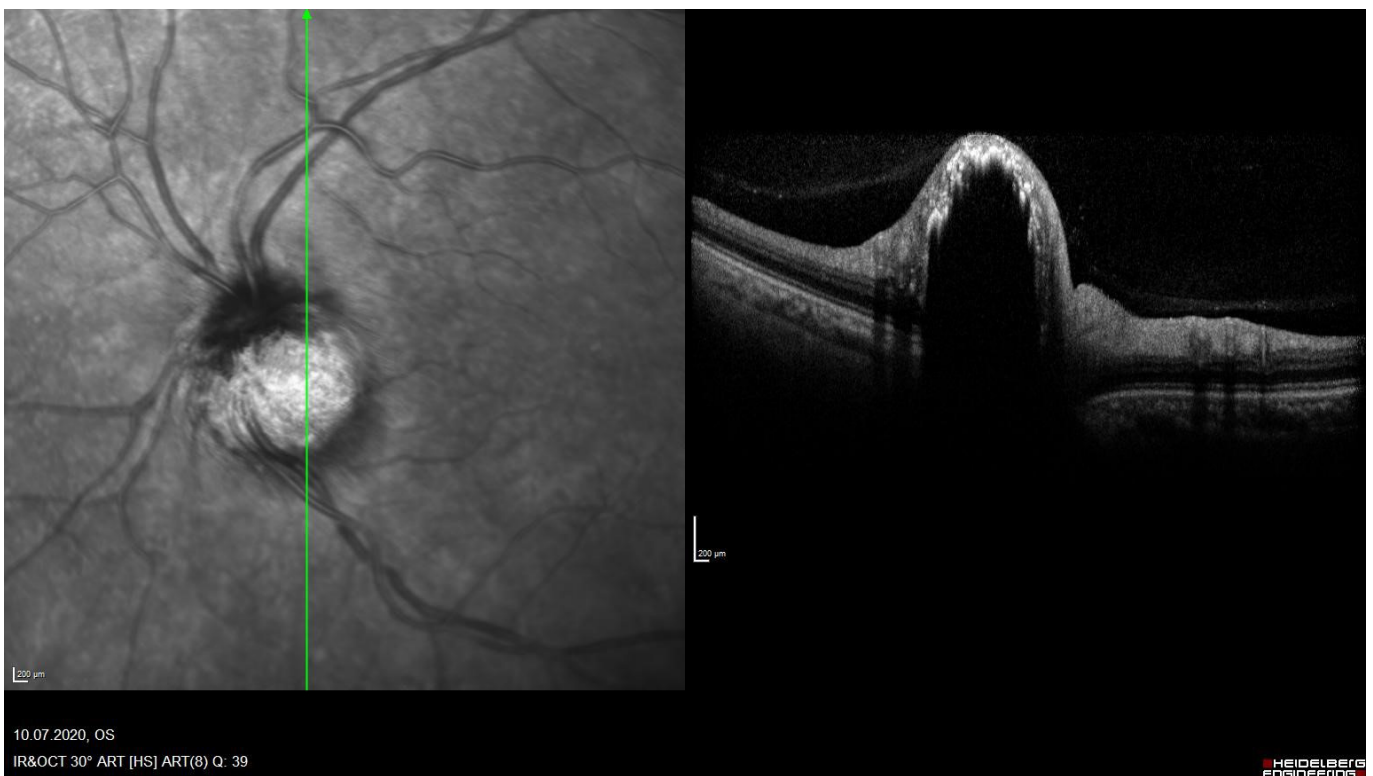
**E-mail:** drslcdlk@gmail.com



**Figure 1a:** Color photography of the right eye shows tilted disc, peripapillary atrophy and chorioretinal atrophy.



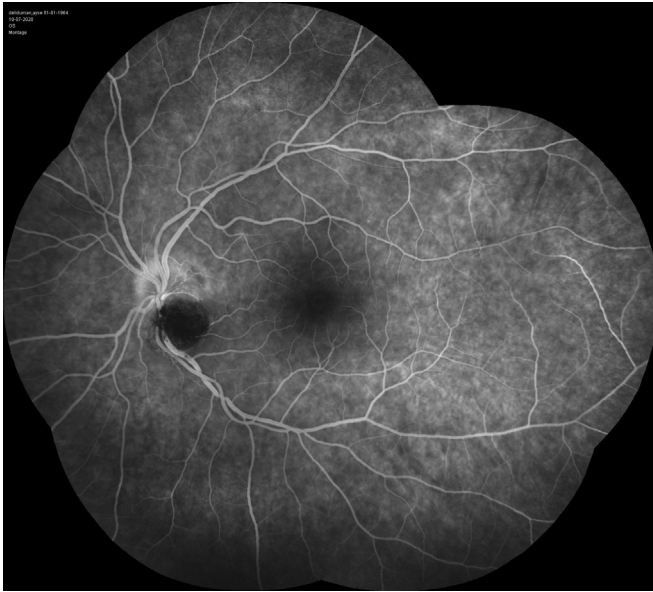
**Figure 1b:** Color photo of the left eye shows dark-pigmented lesion over the inferior margin of optic disc.



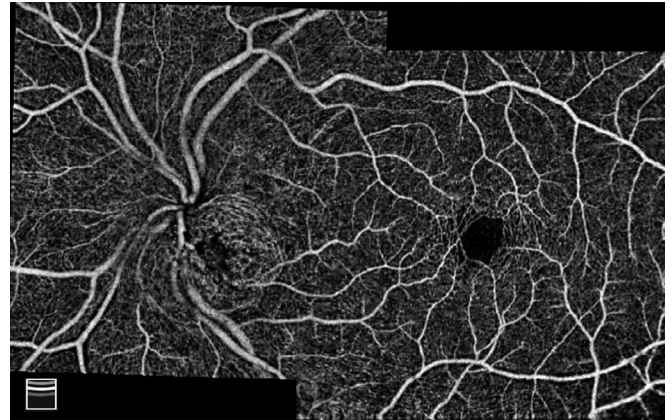
**Figure 2a:** OCT showing dome-shaped lesion within the optic disc with high reflectivity and shadowing effect.

optic disc in the LE. (Figure 2b) Fluorescein angiography showed hypofluorescent lesion at all times due to blockage of fluorescein and late marginal staining. (Figure 3a) OCT-angiography (OCTA) revealed increased tortuous blood vessels and disorganized vasculature within the tumor. (Figure 3b) The axial length of the RE was 30.59 mm,

the axial length of the LE was 21.78 mm in biometric measurements. Staphyloma was observed in the right orbit magnetic resonance imaging (MRI), and no pathology in the left orbit and brain MRI. Enlarged blind spot was seen in the 30-2 visual field of the LE.



**Figure 2b:** B-scan USG of the right eye shows excavation corresponding to posterior staphyloma, and hyperechoic image of melanocytoma over the optic disc of the left eye.

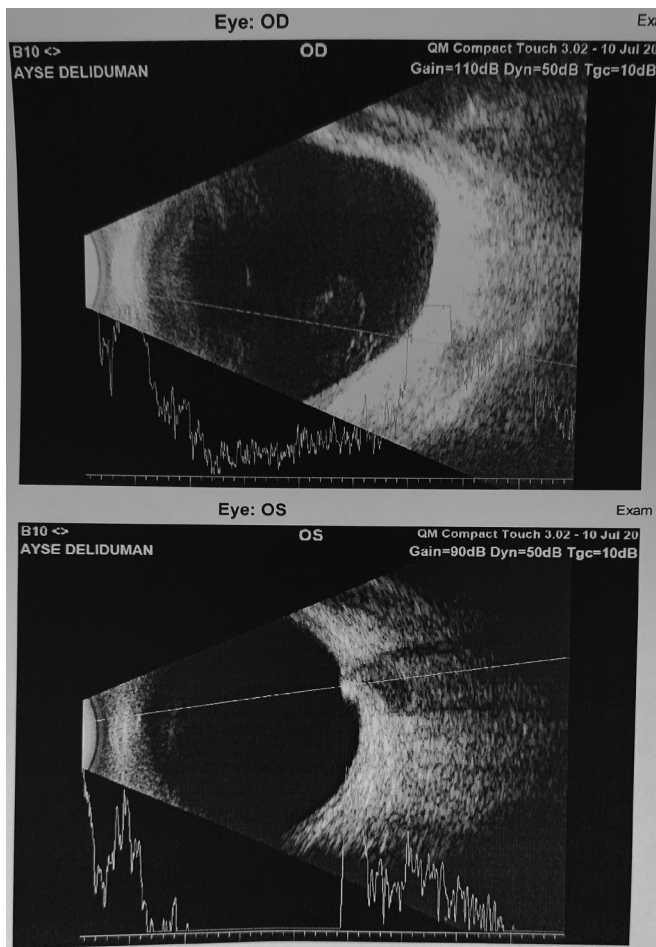


**Figure 3b:** OCTA showing increased tortuous blood vessels and disorganized vasculature within the melanocytoma.

## DISCUSSION

Melanocytoma is a benign and stable hamartoma of uveal tract. Uveal melanoma is mostly seen in the choroid, is less frequent in the anterior uveal tract.<sup>4</sup> There are three case series in the literature involving a significant number of patients. First, in 1962, Garron and Zimmerman reported a study involving 35 cases, 20 of which were enucleated eyes<sup>5</sup>, Joffie et al. had a study with 40 cases<sup>6</sup> and finally, the largest series of 115 cases were reported by Shields et al.<sup>7</sup> While no malignant transformation was found in the first two series, Shields et al. showed 11% growth and 2% malignant transformation in their series. It was also reported to cause various local complications such as optic disc edema, optic disc pallor, retinal edema, subretinal fluid, intraretinal exudation, choroidal neovascularization, retinal hemorrhage, central retinal vein occlusion, retinal artery occlusion and pigment dissemination in vitreous.<sup>7</sup> For these reasons, regular follow-up of patients is required.

Melanocytomas are usually diagnosed unilaterally. Patients diagnosed bilaterally in the literature are generally pediatric patients.<sup>8,9</sup> Optic disc melanocytoma is confined to the optic nerve head in 40%, it has contiguous involvement of the choroid and sensory retina in the rest.<sup>7</sup> Ocular melanosis, optic nerve hypoplasia, retinitis pigmentosa and congenital hypertrophy of the retinal pigment epithelium have been reported in the literature as co-incident ocular pathologies accompanying optic nerve head melanocytoma. But these were thought to be present co-incidentally.<sup>2</sup> Although optic disc melanocytoma is generally an isolated entity with no proof of any systemic association, it has been reported with neurofibromatosis-2, basal cell carcinoma and vitiligo.<sup>8</sup> Cases with intracranial meningioma accompanying by optic disc melanocytoma have also been reported in the literature.<sup>9</sup>



**Figure 3a:** Fluorescein angiography showed blockage of the dye and late marginal staining.

Diagnosis of optic disc melanocytoma is based on ophthalmoscopic features. B-scan USG and OCT helps in follow-up. OCTA is a new non-invasive tool to detect vascular changes associated with malignant transformation.<sup>10</sup> In a study of 10 cases, varying degrees of pigmented melanocytomas were shown to contain intense vascularization within the lesion in the OCTA. Increased vascular and perfusion density was observed in eyes with melanocytoma compared to normal eyes.<sup>10</sup> Similarly, OCTA showed increased tortuous blood vessels and vasculature in our case.

In this study, we present a case with unilateral pathologic myopia accompanying optic disc melanocytoma, which we thought to be co-incidental, as in the other ocular associations of optic disc melanocytoma in previous reports. This is the first reported case of unilateral pathologic myopia accompanying optic disc melanocytoma to the best of our knowledge.

#### Statements on compliance with ethical standards

This study was carried out under research program of Ulucanlar Eye Training and Research Hospital.

The authors of this manuscript named received no financial support or funds and have no financial interests related to this manuscript. This study does not contain animals as subjects.

All procedures performed in studies involving human participants were in accordance with the ethical standards of the institutional and/or national research committee and with the 1964 Helsinki Declaration and its later amendments or comparable ethical standards.

Informed consent was obtained from all individual participants included in the study.

#### REFERENCES

1. Esmaili DD, Mukai S, Jakobiec FA, et al. Ocular melanocytoma. *Int Ophthalmol Clin* 2009;49:165-75.
2. Shields JA, Demirci H, Mashayekhi A, et al. Melanocytoma of the optic disk: a review. *Surv Ophthalmol* 2006;51.
3. Ohno-Matsui K. Pathologic myopia. *Asia Pac J Ophthalmol* 2016;5: 415-23.
4. Brodsky MC: Melanocytoma or congenital optic disk pigmentation? *Am J Ophthalmol* 2004; 137:208-910.
5. Zimmerman le. Melanocytes, Melanocytic nevi, and Melanocytomas. *Invest Ophthalmol*. 1965;4:11-41.
6. Joffe L, Shields JA, Osher RH, et al. Clinical and follow-up studies of melanocytomas of the optic disc. *Ophthalmology* 1979;86:1067-83.
7. Shields JA, Demirci H, Mashayekhi A, et al. Melanocytoma of optic disc in 115 cases: the 2004 Samuel Johnson Memorial Lecture, part 1. *Ophthalmology* 2004;111:1739-46.
8. Demirci H, Shields CL, Shields JA. Bilateral optic disk melanocytoma in a 10-month-old infant. *Am J Ophthalmol* 2003;136.
9. Shinoda K, Hayasaka S, Nagaki Y, et al. Melanocytoma of the left optic nerve head and right retrobulbar optic neuropathy compressed by a tuberculum sellae meningioma. *Ophthalmologica* 2000;214:161-3
10. Zhou N, Xu X, Wei W. Optical coherence tomography angiography characteristics of optic disc melanocytoma. *BMC Ophthalmol* 2020;20:1-8.