

# Bilateral Central Serous Chorioretinopathy After Tooth Extraction

## *Diş Çekimi Sonrası Bilateral Santral Seröz Koryoretinopati*

*Orhan AYAR<sup>1</sup>, Mehmet Cüneyt ÖZMEN<sup>2</sup>,  
Mehmet Orçun AKDEMİR<sup>1</sup>, Serpil YAZGAN<sup>1</sup>,  
Sabite Emine GÖKÇE<sup>3</sup>*

### SUMMARY

A 42-year-old male presented to our clinic with acute blurring of vision in both eyes especially in reading for about 2 weeks. Detailed history revealed that the patient recently applied to his dentist because of tooth ache. The patient's complaints about reading had started 2 weeks after tooth extraction. He had a medication of amoxicillin for a month prior to tooth removal and non-steroidal anti-inflammatory drugs after extraction. In this case we report a bilateral CSCR case after tooth extraction.

**Key Words:** Central serous chorioretinopathy, non-steroidal anti-inflammatory drug, tooth extraction.

### ÖZ

Kırkiki yaşında erkek hasta, yaklaşık 2 haftadır özellikle okurken aniden görme bulanıklaşması ile kliniğimize başvurdu. Detaylı hikâyesinde hastanın diş ağrısı nedeniyle diş hekimine başvurduğu öğrenildi. Hastanın okuma ile ilgili şikâyetleri diş çekiminden 2 hafta sonra başlamıştı. Hasta diş çekilmesinden 1 ay öncesinde amoksisilin, sonrasında 2 hafta süreyle non-steroid anti-inflamatuar ilaç kullanmıştı. Bu vakada diş çekimi sonrasında görülen çift taraflı SSKR olgusu sunulmuştur.

**Anahtar Kelimeler:** Diş çekimi, non-steroid anti-inflamatuar ilaç, santral seröz koryoretinopati.

1. M.D. Asistant Professor, Bulent Ecevit University Faculty of Medicine, Department of Ophthalmology, Zonguldak/TURKEY

AYAR O., orhanayar@gmail.com  
AKDEMİR M.O., doktororcun@yahoo.com  
YAZGAN S., serpily80@gmail.com

2. M.D. Asistant Professor, Gazi University Faculty of Medicine, Department of Ophthalmology, Ankara/TURKEY

ÖZMEN M.C., mcozmen@gmail.com

3. M.D, Special Kudret Eye Hospital, Ankara/TURKEY  
GOKCE S.E., segokce@gmail.com

**Geliş Tarihi - Received:** 16.05.2014  
**Kabul Tarihi - Accepted:** 22.07.2014  
*Ret-Vit Özel Sayı 2015;23:151-154*

**Yazışma Adresi / Correspondence Address:**  
M.D. Asistant Professor, Orhan AYAR  
Bulent Ecevit University Faculty of Medicine, Department of Ophthalmology, Zonguldak/TURKEY

**Phone:** +90 372 261 30 95  
**E-Mail:** orhanayar@gmail.com

## INTRODUCTION

Central serous chorioretinopathy (CSCR) is an idiopathic serous detachment of the neurosensory retina in the macular region. The disease typically affects patients between ages 20-50 and males are more affected than females.<sup>1</sup> Fluid leaking from the choriocapillaris through the retinal pigment epithelium into the subretinal space cause the neurosensorial detachment. The exact pathogenesis is still unclear but there are two main theories. One of them is retinal pigment epithelial (RPE) cell dysfunction that fluid can not be pumped away from the retina and the other theory is fluid accumulation in the RPE due to the hyperpermeability of the choroidal circulation.

The conditions associated with CSCR are Type A personality, pregnancy, Cushing's syndrome, corticosteroids, sympathomimetic drugs, and increased levels of circulating serum catecholamines.<sup>2</sup> Moreover antibiotic and alcohol use and allergic respiratory disease are rare conditions associated with CSCR. The disease is generally self-limited, and most patients have spontaneous resolution within 6 months.<sup>3</sup>

The primary goal of treatment is to determine the underlying risk factors and properly struggle with them. Other treatments include focal laser photocoagulation and photodynamic laser therapies.<sup>4,5</sup> However, because of limited benefits and potential side-effects, neither of these modalities regularly take part in the treatment. In this report we present a CSCR case after tooth extraction.

## CASE REPORT

A 42-year-old male presented to our clinic with acute blurring of vision in both eyes (OU) especially in reading for about 2 weeks. At presentation to our clinic his best corrected visual acuity (BCVA) was 20/20 (OU) with hyperopic correction (+1.0). Fundus examination revealed bilateral central serous retinal elevation in the macular region.

The rest of the ocular examination was unremarkable. Optical coherence topography (OCT) showed bilateral macular detachment and subretinal fluid (Figure 1) and fluorescein angiography (FA) confirmed the diagnosis of CSCR with window defects, multiple late leakage in both eyes and RPE atrophy area extending to papillary region in the left eye (Figure 2,3).

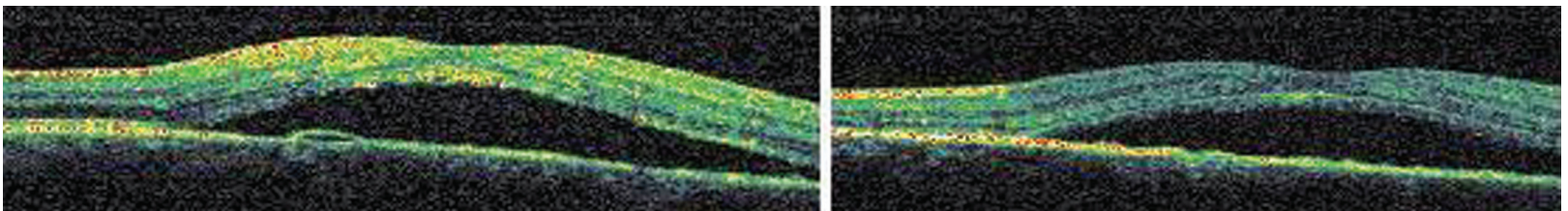
Detailed history revealed that the patient recently applied to his dentist because of tooth ache and had a medication of amoxicillin for a month prior to tooth removal.

Two weeks after tooth extraction he had sudden loss of near vision. During this period the patient had used non-steroidal anti-inflammatory drugs.

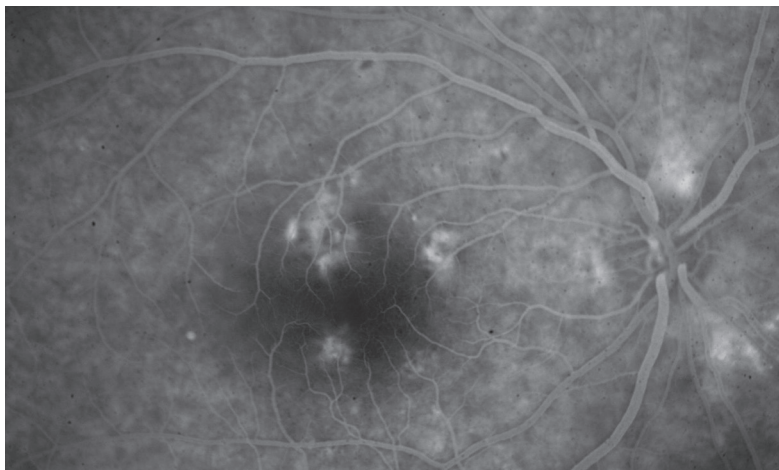
He had no history of corticosteroid drugs. Because the initial visual acuity was good, only topical treatment was considered. Ketorolac trometamin QID was prescribed.

## DISCUSSION

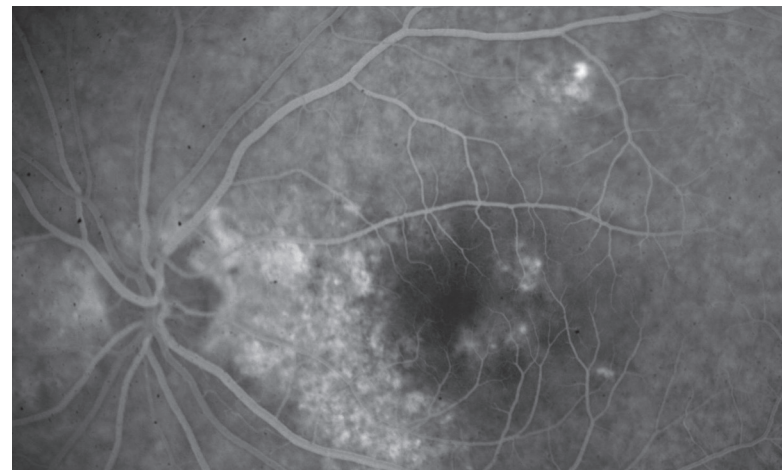
The etiology and pathogenesis of CSCR is still unclear. Presentation may vary from asymptomatic to blurred vision, meta-



**Figure 1:** OCT images show bilateral macular detachment and a pigment epithelial detachment on the right eye.



**Figure 2:** FFA demonstrates bilateral window defects and multiple late leakage in the macular region in right eye.



**Figure 3:** FFA demonstrates bilateral window defects, multiple late leakage in the macular region and RPE atrophy area extending to papillary region in left eye.

morphopsia, micropsia and colour desaturation. Visual acuity is 20/30 on average but range from 20/15 to 20/200. Slight hyperopic correction usually improves vision and this may delay the diagnosis. Stress, steroids, pregnancy, Cushing's syndrome, systemic hypertension, lupus erythematosus, antibiotics, alcohol and allergic respiratory disease have been implicated in the causes of CSCR.<sup>6</sup> In addition endogen hypercortisolism was presented as a cause of bilateral CSCR in rare cases.<sup>7</sup>

Diagnosis of CSCR is made clinically and confirmed with optical coherence tomography, fundus fluorescein angiography and indocyanine green angiography (ICGA). Typical OCT finding is serous detachment of macula. FA shows late leakage in the macula with characteristic smokestack patterns only in %10-15 CSCR patients. ICGA shows hypofluorescent areas early in the angiogram followed by late hyperfluorescence and leakage in choroidal vasculature.<sup>1</sup> The choroid probably plays a significant role in the pathogenesis of CSCR.

The choroid is thought to be hyperpermeable in CSCR as shown in ICGA. Thickening of the choroid in both eyes with CSCR is also indicated by EDI-OCT imaging.<sup>8</sup> Increased tissue hydrosta-

tic pressure caused by hyperpermeable choroidal vessels leads to retinal pigment epithelial detachments (PEDs), breaks down the barrier function of the RPE causing fluid accumulation between the retina and the RPE.<sup>9</sup> The initial management is observation in most cases. If systemic or local corticosteroids are being used they have to be discontinued or tapered down. Photodynamic therapy and focal laser photocoagulation are very effective treatments and should be considered in severe cases. In our case there is no history of systemic or local corticosteroid use.

The possible reasons include endogenous increase of catecholamine as a result of tooth extraction, the usage of antibiotic and non-steroidal anti-inflammatory drugs. Non-steroidal anti-inflammatory drugs have not been previously indicated as a risk factor in this disease and they would also be assessed in the etiology with the same unclear mechanism of corticosteroid use.

**REFERENCES/KAYNAKLAR**

1. Gass JDM. Stereoscopic Atlas of Macular Disease. 4th ed. 1997:52-70.
2. Bouzas EA, Karadimas P, Pournaras CJ. Central serous chorioretinopathy and glucocorticoids. *Surv Ophthalmol* 2002;47:431-48.
3. Ryan SJ, Hinton D, Schachat A, et al. *Retina*, 4th Edition. Elsevier, Philadelphia 2006;1135-61.
4. Ficker L, Vafidis G, While A, et al. Long-term follow-up of a prospective trial of argon laser photocoagulation in the treatment of central serous retinopathy. *Br J Ophthalmol* 1988;72:829-34.
5. Ober MD, Yannuzzi LA, Do DV, et al. Photodynamic therapy for focal retinal pigment epithelial leaks secondary to central serous chorioretinopathy. *Ophthalmology* 2005;112:2088-94.
6. Haimovici R, Koh S, Gagnon DR, et al. Central Serous chorioretinopathy case-control study group. risk factors for central serous chorioretinopathy: a case-control study. *Ophthalmology* 2004;111:244-9.
7. Wang BZ, Saha N. Bilateral multifocal central serous chorioretinopathy in endogenous hypercortisolism. *Clin Exp Optom* 2011;94:598-9.
8. Mendrinos E, Mavrakanas N, Dang-Burgener NP, et al. Bilateral multifocal retinal pigment epithelium detachments associated with systemic corticosteroids. *Eur J Ophthalmol* 2008;18:649-51.
9. Imamura Y, Fujiwara T, Margolis R, et al. Enhanced depth imaging optical coherence tomography of the choroid in central serous chorioretinopathy. *Retina* 2009;29:1469-73.
10. Nicholson B, Noble J, Forooghian F, et al. Central serous chorioretinopathy: update on pathophysiology and treatment. *Surv Ophthalmol* 2013;58:103-26.