

# Optical Imaging of Nanophthalmos Associated with Papillomacular Folds and Narrow Anterior Chamber

## Papillomaküler Katlantılar ve Dar Ön Kamara ile Birlikte Gösteren Nanoftalmus Vakasında Optik Görüntüleme

Özgün Melike TOTUK GEDAR<sup>1</sup>, Zeynep GÖKÇE<sup>2</sup>, Ümit AYKAN<sup>3</sup>

### ABSTRACT

Nanophthalmos is a rare condition presented with a short axial length and relatively normal anterior segment findings. Evaluation with optical coherence tomography (OCT) and optical biometer will be helpful in the diagnosis and determination of the associated sight threatening clinical findings in nanophthalmos cases. A 5 years old female presented with high hypermetropia, astigmatism and decreased visual acuity. Evaluation with a complete ophthalmological examination including OCT and swept source optical biometer yielded short axial length, horizontal papillomacular folds, narrow anterior chamber angle with normal intraocular pressure and anterior chamber depth. Detailed examination, proper noncontact anterior and posterior segment OCT and swept source optic biometer evaluations are mandatory and are easy tools to reach accurate diagnosis and to detect potential complications of nanophthalmos cases even in a child.

**Key Words:** Nanophthalmos, Papillomacular folds, Optical coherence tomography, Narrow angle glaucoma, Swept source optical biometer.

### ÖZ

Nanoftalmus kısa aksiyel uzunluk ve nispeten normal ön segment bulguları ile görülen nadir bir durumdur. Nanoftalmuslu olgularda optik koherens tomografi (OKT) ve optik biyometri ile yapılan değerlendirme, hastalığın tanısında ve görmeyi tehdit eden klinik bulguların belirlenmesinde yardımcı olur. 5 yaşında kadın hasta yüksek hipermetropi, astigmatizma ve görme keskinliğinde azalma ile başvurdu. OKT ve swept source optik biyometri dahil olmak üzere tam bir oftalmolojik muayene ile değerlendirmede ile kısa aksiyel uzunluk, yatay papillomaküler katlantılar, normal göz içi basıncı ve normal ön kamara derinliği ile dar ön kamara açısı tespit edildi. Çocukluk çağında bile nanoftalmus olgularının tanısını doğru koymak ve olası komplikasyonlarını saptamak için ayrıntılı muayene, uygun nonkontakt ön ve arka segment OKT ve swept source optik biyometri değerlendirmelerinin uygulaması kolay ve zorunludur.

**Anahtar Kelimeler:** Nanoftalmus, Papillomaküler katlantılar, Optik koherens tomografi, Dar açılı glokom, Swept source optik biyometri.

### INTRODUCTION

Nanophthalmos and posterior microphthalmos, a relatively rare abnormality both sometimes termed simple microphthalmos are described as corneal diameter being more than 10 mm with the axial length (AL) varying from 16 to 18mm in an otherwise normal eye. Narrow palpebral fissure, a deeply set globe in a small orbit, high axial hypermetropia in the range of 15 to 20D, narrow or grossly normal anterior chamber, normal visual acuity

unless occurrence of retinal complications or amblyopia, relatively large for the globe but normal sized lens, tortuous and engorged retinal vessels are other clinical characteristics of nanophthalmos. The other pathologies accompany and decrease visual acuity in nanophthalmos are macular atrophy, horizontal papillomacular folds, crowded optic nerve head and uveal effusion. Although patients have normal anterior chamber and intraocular pressure (IOP) at diagnosis, they often develop narrow angle glaucoma with time during childhood.<sup>1</sup>

1- MD, Asst Prof., Bahçeşehir University Medical School, Department of Ophthalmology, İstanbul, Türkiye

2- 4<sup>th</sup> Grade Medical Student, Bahcesehir University Medical School, İstanbul, Türkiye

3- MD, Prof, FEBO., Dünyagöz Hospital, Department of Ophthalmology, İstanbul, Türkiye

Geliş Tarihi - Received: 05.06.2018

Kabul Tarihi - Accepted: 25.07.2018

Ret-Vit 2019; 28: 310-313

Yazışma Adresi / Correspondence Address:

Özgün Melike TOTUK GEDAR

Bahçeşehir University Medical School, Department of Ophthalmology, İstanbul, Türkiye

Phone: +90 216 579 8195

E-mail: melikegedar@gmail.com

Herein we described a nanophthalmos case in a child with high hypermetropia, short AL, horizontal papillomacular folds, and narrow anterior chamber angle diagnosed with optic coherence tomography (OCT) and swept source (SS) optical biometer.

**CASE REPORT**

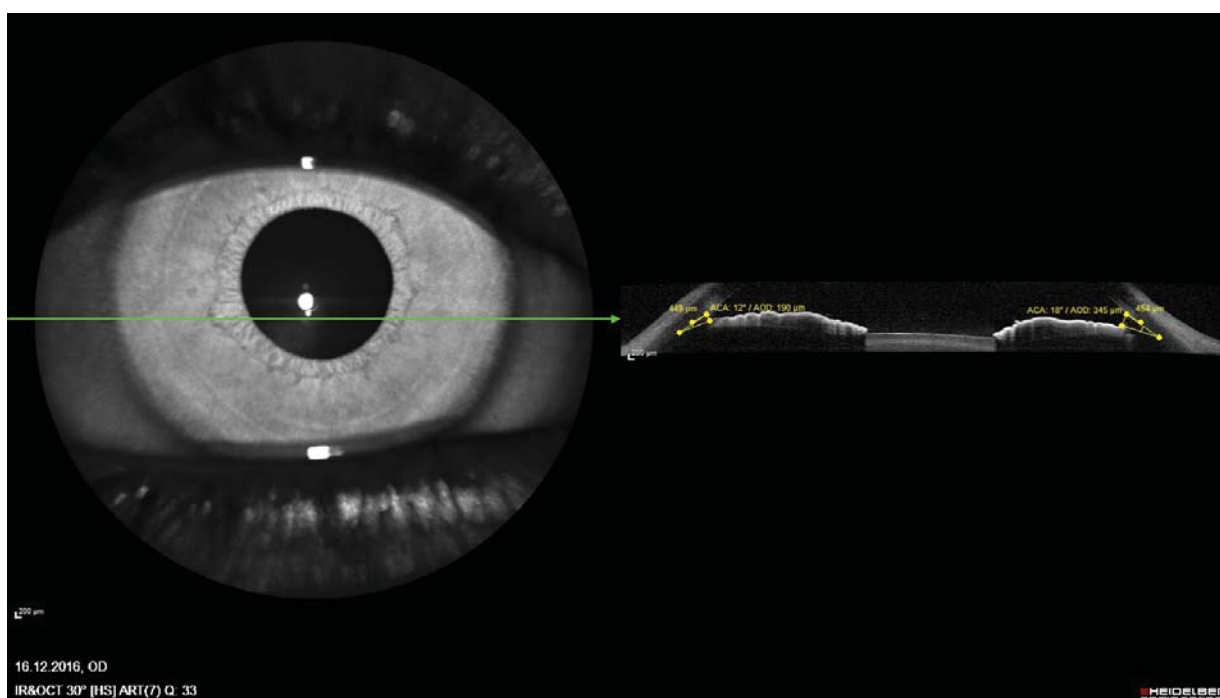
A 5 years old female with unremarkable past medical history is presented with high hypermetropia and astigmatism. Table 1 shows ocular examination and intraocular dimensions results of the patient.

The van Herrick test was performed and resulted as grade 2 narrow anterior chamber angle with normal IOP's and anterior chamber depth (ACD) and it was shown in anterior segment (AS) OCT scans (Figure 1). Eye movements were normal in all directions and eyes were orthophoric. Fundusoscopic examination showed increased retinal tortuosity and engorged vessels in both eyes and OCT revealed horizontal papillomacular bundle folds in both eyes (Figure 2). A diagnosis of nanophthalmos was entertained based on the above-mentioned findings.

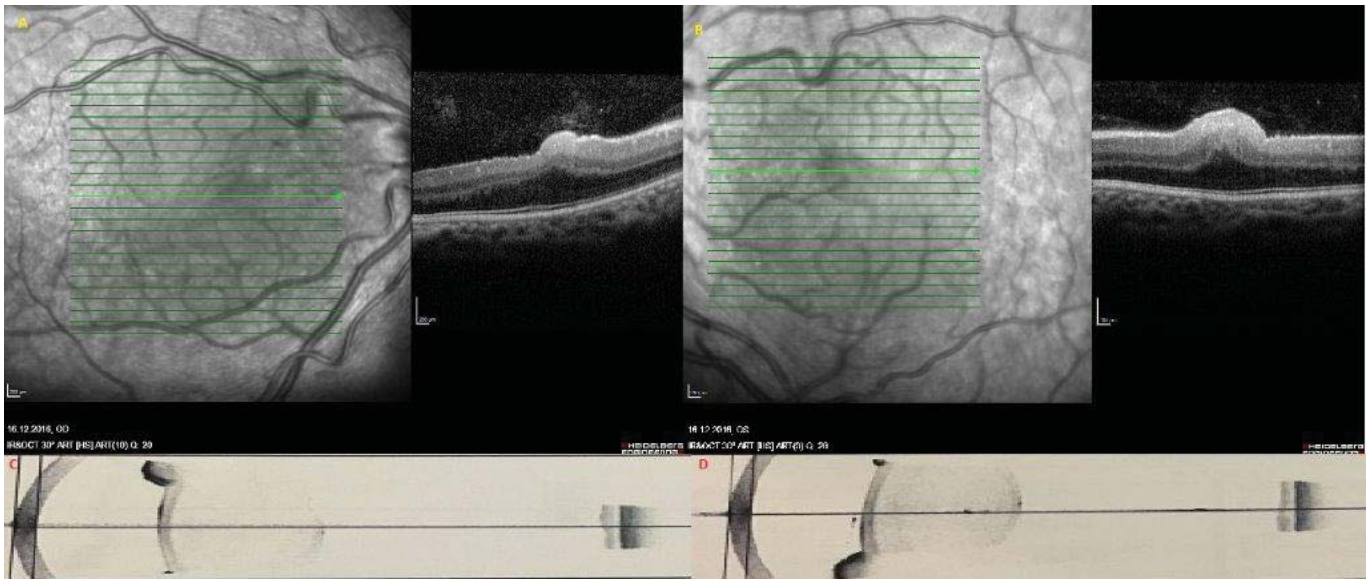**Table 1. Ocular examination findings and intraocular measurements of the nanophthalmos patient**

	Right Eye	Left Eye
Refraction	+19.50 -0.75x159 D	+19.75 -0.50x11 D
Dilated Refraction	+26.50 -1.50x160 D	+27.00 -2.25x10 D
BCVA	4/10	3/10
K1	51.23@171	51.16@20
K2	52.80@81	52,35@110
WTW	11.7mm	11.4mm
AL	14.64±0.18 mm	n/a
ACD	3.52±0.6 mm	n/a
LT	3.91 mm	n/a
IOP	16 mmHg	16 mmHg
CCT	514 µm	511 µm

**D:** Diopters, **BCVA:** Best corrected visual acuity (Snellen), **K:** Keratometry, **WTW:** White-to-white (corneal diameter), **AL:** Axial length, **ACD:** Anterior chamber depth, **LT:** Lens thickness, **IOP:** Intraocular pressure, **CCT:** Central corneal thickness. K, WTW, AL, ACD, LT and WTW measurements derived from SS-OCT (The Zeiss IOLMaster®700)



**Figure 1.** Anterior segment OCT scan of right eye shows narrow anterior chamber angle with the SPECTRALIS®OCT (Heidelberg Engineering).



**Figure 2.** Posterior segment OCT scan shows papillomacular folds with the SPECTRALIS® OCT (Heidelberg Engineering) A: right eye B: left eye; and full length longitudinal cut with the Zeiss IOLMaster® 700.

## DISCUSSION

Nanophthalmos or posterior microphthalmos can be complicated by various posterior segment changes such as pigmentary retinopathy, bull's eye maculopathy, macular hypoplasia, retinal and macular cysts, elevated papillomacular retinal folds, and uveal effusion syndrome. Anterior and posterior segment imaging devices are needed to achieve accurate diagnosis and meticulous follow-up is mandatory to keep visual acuity in nanophthalmos patients.<sup>2</sup> It is suggested that retinal folds in nanophthalmos eventuate as a result of arrested scleral development and continuation of retinal development.<sup>3</sup> In our case the most probable reasons of the visual loss were papillomacular retinal folds and amblyopia due to high hypermetropia.

AL measurement is helpful in the diagnosis of nanophthalmos. Optical biometers are superior to acoustic ultrasound (AUS) biometers due to ease of use even in relatively young patients, accuracy and reproducibility as well as the non-contact nature of the procedure.<sup>4</sup> The Zeiss IOLMaster®700 using SS technology measures AL in complete longitudinal section of the eye giving ranges between 14-38 mm.<sup>5</sup> But in our case the IOLMaster®700 could not measure the AL of the left eye. This could be because of the left eye's AL being less than 14 mm or papillomacular folds interfering with the measurement of the AL. As the optical biometers measure AL from cornea to photoreceptor layers, thickening of the retina and presence of papillomacular folds in our patient might have resulted in inability to measure the AL of the left eye. In that case immersion contact ultrasonic biometer could be used to measure the AL, but since the patient's age was not suitable for using a contact method and it was not really necessary for the confirmation of the diagnosis plus there was not a planned cataract surgery at that point, we did not use the

immersion ultrasonic biometer.

Angle-closure glaucoma (ACG) is the leading cause of reduced vision in adult nanophthalmos patients with the mechanism of relative pupillary block which starts with an anatomical predisposition to angle closure due to the angle's narrowness or a relatively increased lens thickness and appositional closure progresses to peripheral anterior synechiae (PAS) formation. At the early stages of ACG, laser iridotomy and argon laser peripheral iridoplasty are the first choices of treatment. Intraocular glaucoma surgery carries serious sight threatening risks like massive uveal effusion, retinal detachment, intraocular hemorrhage, and malignant glaucoma and should be considered as the last treatment option.<sup>6</sup> Any intraocular surgery in a nanophthalmos patient can be complicated by uveal effusion and macular edema.<sup>7</sup> Uveal effusion may cause ciliary body annular detachment and further ACG.<sup>6</sup> AS-OCT is the best method for detecting anterior segment structures as well as iridocorneal angle with ease of use and non-contact modality.<sup>8</sup> In our case, although ACD seemed to be in normal range with SS biometer, anterior chamber angle was demonstrated to be narrow with AS-OCT. As the IOP's were at normal range, narrow anterior chamber detected by AS-OCT gave us notice for close follow-up for glaucoma progression and keeping in mind the potential complications of intraocular surgery in our patient.

Detailed ophthalmologic examination with anterior and posterior segment OCT and SS optic biometer evaluations are helpful in confirmation of accurate diagnosis and in detection of potential complications of nanophthalmos cases even in a child with ease of use, rapid and noncontact modality.

**REFERENCES / KAYNAKLAR**

1. Traboulsi EI. Compendium of Inherited Disorders and the Eye. New York: Oxford University Press; 2005.
2. Khairallah M, Messaoud R, Zaouali S, et al. Posterior segment changes associated with posterior microphthalmos. *Am J Ophthalmol* 2002;109:569-74.
3. Boynton JR, Purnell EW. Bilateral microphthalmos without microcornea associated with unusual papillomacular retinal folds and high hyperopia. *Am J Ophthalmol* 1975;79:820-6.
4. Nakhli FR. Comparison of optical biometry and applanation ultrasound measurements of the axial length of the eye. *Saudi J Ophthalmol* 2014;28:287-91.
5. Gedar Totuk OM, Aykan U. Repeatability of the new swept source optical biometer IOLMaster®700 measurements. *Int J Adv Res* 2017;6:4627-31.
6. Yalvac IS, Satana B, Ozkan G, et al. Management of glaucoma in patients with nanophthalmos. *Eye* 2008;22:838-43.
7. Moradian S, Kanani A, Esfandiari H. Nanophthalmos. *J Ophthalmic Vis Res* 2011;6: 145-6.
8. Radhakrishnan S, Goldsmith J, Huang D, et al. Comparison of optical coherence tomography and ultrasound biomicroscopy for detection of narrow anterior chamber angles. *Arch Ophthalmol* 2005;123:1053-9.