

A Case of Unilateral Retinitis Pigmentosa with Lamellar Macular Hole

Hasan KIZILTOPRAK¹, Kemal TEKIN², Mehmet Yasin TEKE³

ABSTRACT

Unilateral retinitis pigmentosa (RP) is rare condition and may occur due to genetic mosaicism, which may affect only some cells, or develop somatic mutation instead of germinal mutation. A 28-year-old female patient who had had no history of systemic disease, trauma, drug use, or intraocular surgery had progressive vision loss and nyctalopia in her right eye. Her anterior and posterior segment examination revealed posterior subcapsular cataract and RP with lamellar macular hole (MH) in the right eye. Surgery was planned and after phacoemulsification and intraocular lens implantation as well as pars plana vitrectomy with internal limiting membrane peeling, the lamellar MH was completely closed and the foveal contour is formed. Many macular abnormalities can be seen in unilateral RP cases. It is of great importance to detect these macular pathologies early to apply appropriate treatment and to prevent the addition of central visual field to peripheral visual field lost due to RP.

Keywords: Lamellar macular hole, Psödoretinitis pigmentosa, Retinis pigmentosa.

INTRODUCTION

Retinitis pigmentosa (RP) is a group of hereditary retinal dystrophies characterized by the progressive peripheral and central vision loss with rod and cone photoreceptor degeneration.¹ In patients with RP, retinal degeneration starting in rod photoreceptors is then included in cone photoreceptors and serious visual loss occurs.¹ Unilateral RP is characterized by retinitis pigmentosa-like changes in one eye, and the other is completely normal.² To diagnose the unilateral RP, it is necessary to exclude diseases that mimicing RP, and support this diagnosis with electroretinography (ERG).³

Although RP causes severe visual impairment due to photoreceptor degeneration, concomitant pathologies may contribute to this impairment. During the course of RP, the macular area is generally preserved to its late stages, but there are significant macular changes associated with RP in the course of the disease. The most common macular abnormalities are cystoid macular edema and macular holes (MH).⁴ Other vitreoretinal interface changes such as

persistent vitreous traction and epiretinal membranes have also been reported.^{4,5}

In this case, we wanted to present our approach to the accompanying lamellar MH in a case of unilateral RP.

CASE PRESENTATION

A 28-year-old woman was referred to the retina department with the complaint of decreased vision in the right eye. In her history, it was learned that the patient had been experiencing a permanent decrease in her vision for the last 10 years. She also stated that she had a reduced vision at night since she was 15 years old. The patient had no history of systemic disease, trauma, drug use or intraocular surgery. His best-corrected visual acuity (BCVA) was counting fingers from 2 meters on the right and 10/10 on the left; IOP values were 14 mmHg on the right and 13 mmHg on the left eye. While the biomicroscopic examination revealed posterior subcapsular cataract in the right eye, the left eye was completely normal. In the fundus examination with dilatation, despite the right eye fundus was not fully evaluated, RP was observed and the left eye was completely normal (Figure 1). On horizontal macular

1- Ophthalmologist, Ankara Ulucanlar Training and Research Hospital, Ophthalmology Department, Ankara, Turkey

2- Ophthalmologist, Ercis City Hospital, Ophthalmology Department, Van, Turkey

3- Associate Prof., MD., Ankara Ulucanlar Training and Research Hospital, Ophthalmology Department, Ankara, Turkey

Received: 21.02.2019

Accepted: 03.08.2019

Ret-Vit 2020; 29: 157-161

DOI:10.37845/ret.vit.2020.29.28

Correspondence Address:

Hasan KIZILTOPRAK

Ankara Ulucanlar Training and Research Hospital, Ophthalmology Department, Ankara, Turkey

Phone:

E-mail: hsnkzltprk21@gmail.com

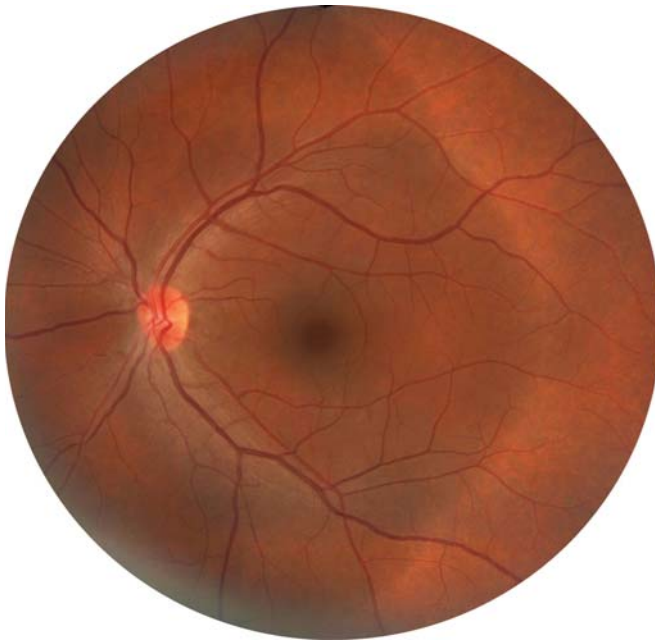


Figure 1: Colored fundus photograph of the left eye was normal.

optical coherence tomography (OCT) scan of the right eye, lamellar MH was observed. However, any pathology was not observed in the left eye (Figure 2).

It was decided to undergo surgical intervention because the visual acuity in the right eye of the patient was related to unilateral RP and the accompanying posterior subcapsular cataract and lamellar MH. In addition to phacoemulsification and intraocular lens implantation, pars plana vitrectomy and internal limiting membrane peeling with gas tamponade were applied in the same session. In the colored fundus photograph taken 2 months postoperatively, extensive RPE changes covering the entire periphery in the form of bone corpuscles, thinning of the vessels, waxy pallor optic disc atrophy are observed (Figure 3). In the vertical macular OCT taken, it is observed that the lamellar hole is closed and the foveal contour is formed (Figure 4). In fundus autofluorescence (FAF) imaging, areas with retina pigment epithelium (RPE) atrophies in the right eye are seen as hypofluorescence, while the left eye is seen as normal (Figure 5). Fluorescein angiography

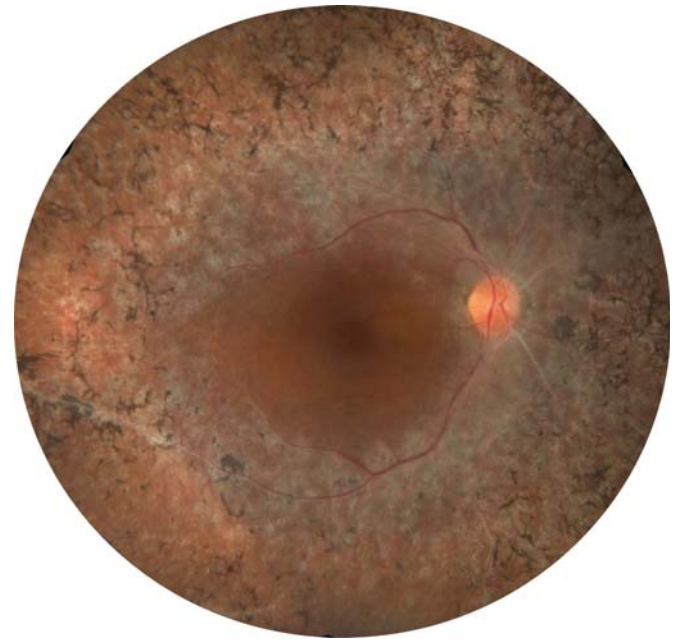


Figure 3: Colored fundus photograph taken 2 months postoperatively, extensive RPE changes covering the entire periphery in the form of bone corpuscles, thinning of the vessels, waxy pallor optic disc atrophy are observed.

revealed hyperfluorescence in areas with RPE atrophies and hypofluorescence in areas with RPE hypertrophy in the right eye. No leakage or staining was observed in the left eye (Figure 6). While there was no ERG response for both cones and rods in the right eye, they were normal in the left eye (Figure 7). The BCVA was 2/10 at postoperative 2 months.

DISCUSSION

Unilateral RP is a rare type of rod-con dystrophy and was first described in 1948.⁶ As known; retinal dystrophies are frequently bilateral. In some cases, genetic mosaicism may cause mutation to affect only some cells, or development of a somatic mutation rather than a germinal mutation may be the cause of unilateral disease.⁷

The diagnosis of unilateral RP has difficulties due to many reasons mimicing RP. Unilateral pseudo RP may occur due

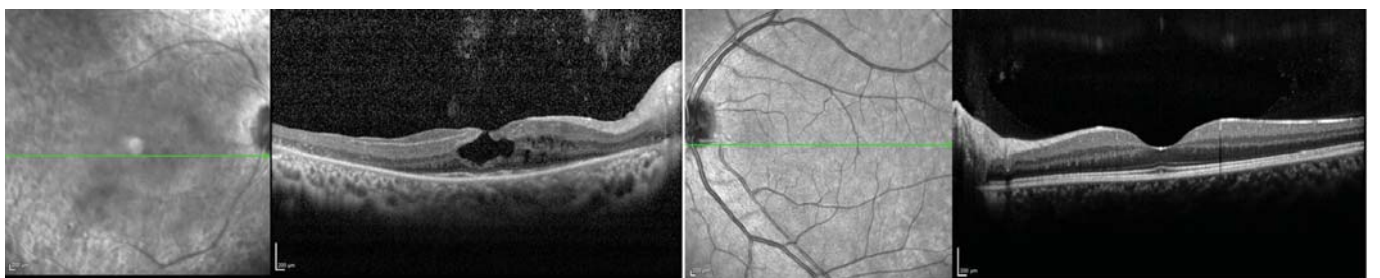


Figure 2: Composite horizontal macular optical coherence tomography revealed lamellar MH on the right and no pathology was observed in the left eye.

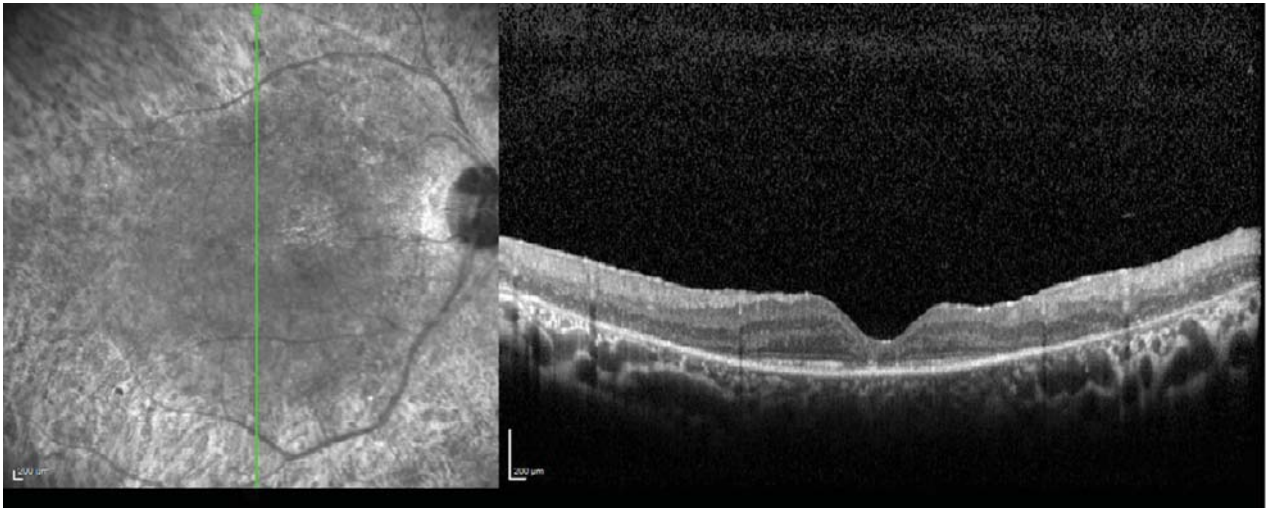


Figure 4: In vertical macular optical coherence tomography two months postoperatively, it is observed that the lamellar hole is closed and the foveal contour is formed.

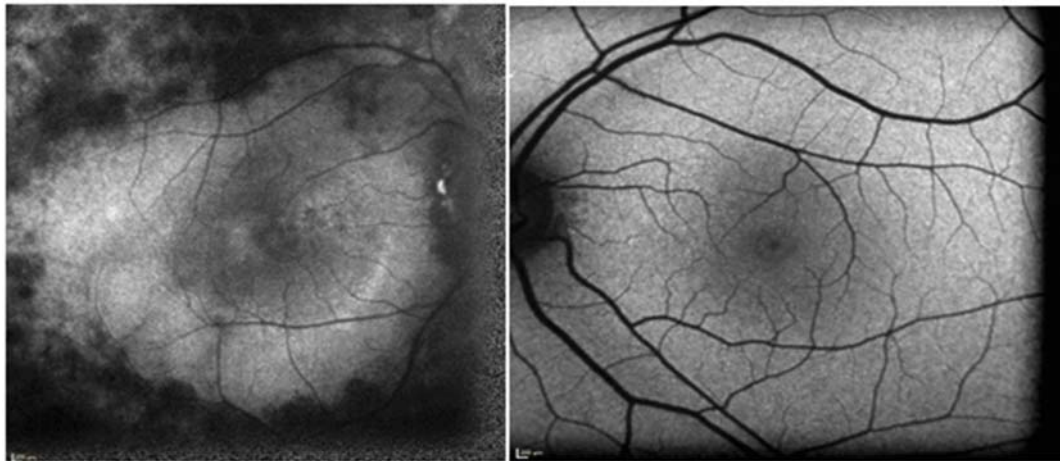


Figure 5: In fundus autofluorescence imaging, areas with RPE atrophies in the right eye are seen as hypofluorescence, while the left eye is seen as normal.

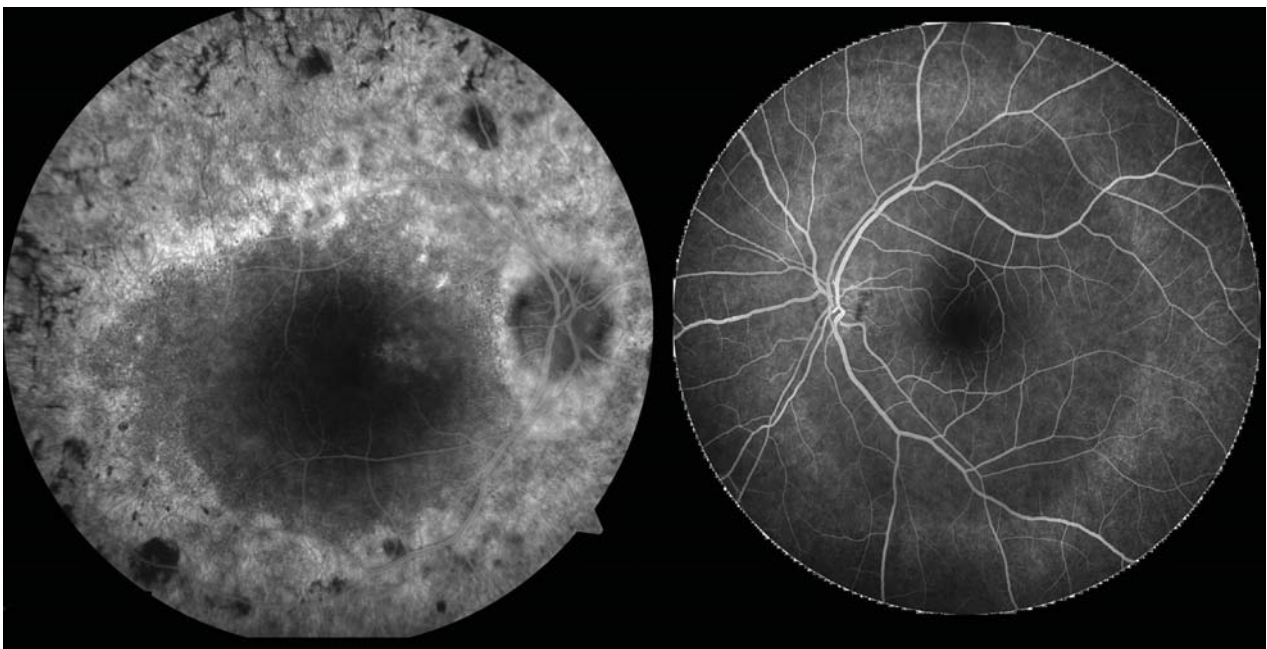


Figure 6: Fluorescein angiography revealed hyperfluorescence in areas with RPE atrophies and hypofluorescence in areas with RPE hypertrophy in the right eye. No leakage or staining was observed in the left eye.

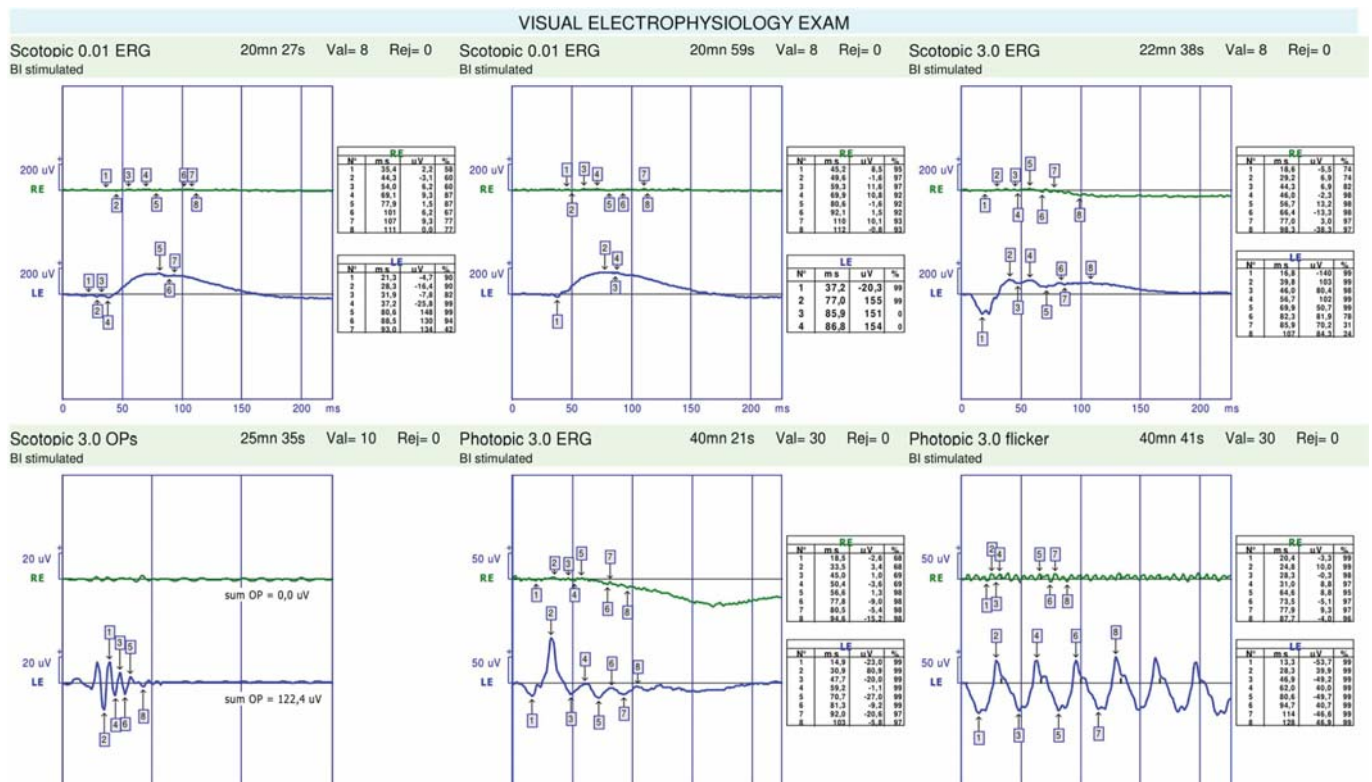


Figure 7: There was no ERG response for both cones and rods in the right eye, however they were normal in the left eye.

to ocular infections (syphilis, rubella), toxic retinopathies (use of phenothiazine, use of hydroxychloroquine), central retinal vein occlusion, traumatic retinopathy, intraocular foreign body and carcinoma-associated retinopathy.⁸ For this reason, François and Verriest have determined some criteria including the presence of characteristic RP findings in one eye; absence of any involvement supported by ERG in the other eye; the absence of an infectious, inflammatory and vascular etiology mimicking RP; and a follow-up of at least 5 years in which RP-like findings may occur in the other eye.⁹ In our case, there was no history of cranial and orbital trauma, drug use or surgery. In addition, infectious and inflammatory causes were excluded by examining clinical tests and epidemiological data. ERG was performed and it was decided that the patient was unilateral.

In RP cases, many vitreoretinal interface problems lead to the addition of central vision loss to the peripheral vision loss due to the disease, leading to significant visual problems. Although cystoid macular edema is common, MH can be seen. Although the mechanism of MH formation is not fully understood, chronic blood-retinal barrier damage, the inner surface of the retina and the irregularities of internal limiting membrane may be blamed.¹⁰ Different levels of MH formation can be seen due to the tendency of macular cysts to coalesce and ILM irregularities leading to traction.⁵ In these cases treatment approach is usually vitrectomy. Enani et al.⁵ performed a

vitrectomy in a case of unilateral RP with full thickness MH. They stated that although they did not achieve any visual increase, surgery prevented further deterioration of foveal function and helped to provide better parafoveal fixation.⁵ Similarly, in our case, we performed surgery to remove lamellar MH from the accompanying traction and to prevent further deterioration of the foveal function. After surgery, we achieved a successful result both anatomically and functionally.

As a result; many macular abnormalities can also be seen in unilateral RP cases and accompanying vitreoretinal interface problems should be investigated after a true unilateral RP diagnosis. It is of great importance to detect these macular pathologies early to apply appropriate treatment and to prevent the addition of central visual field to peripheral visual field lost due to RP.

Ethics

Informed Consent: It was taken from patient or legal guardians.

Conflict of Interest: No conflict of interest was declared by the authors.

Financial Disclosure: The authors declared that this study received no financial support.

REFERENCES

- 1- Hartong DT, Berson EL, Dryja TP. Retinitis pigmentosa. *Lancet* 2006;368:1795-809.
- 2- Marsiglia M, Duncker T, Peiretti E, et al. Unilateral retinitis pigmentosa: a proposal of genetic pathogenic mechanisms. *Eur J Ophthalmol*. 2012;22:654-60.
- 3- Spadea L, Magni R, Rinaldi G, et al. Unilateral retinitis pigmentosa: Clinical and electrophysiological report of four cases. *Ophthalmologica* 1998;212:350-4.
- 4- Hagiwara A, Yamamoto S, Ogata K, et al. Macular abnormalities in patients with retinitis pigmentosa: Prevalence on OCT examination and outcomes of vitreoretinal surgery. *Acta Ophthalmol* 2011;89:122-5.
- 5- Enani L, Kozak I, Abdelkader E. A Case of Unilateral Retinitis Pigmentosa Associated with Full Thickness Macular Hole. *Middle East Afr J Ophthalmol*. 2017;24:113-5.
- 6- Dreisler KK. Unilateral retinitis pigmentosa: two cases. *Acta Ophthalmol*. 1948;26:385-93.
- 7- Bawankar P, Deka H, Barman M, et al. Unilateral retinitis pigmentosa: clinical and electrophysiological diagnosis. *Can J Ophthalmol*. 2018;53:94-7.
- 8- Weller JM, Michelson G, Juenemann AG. Unilateral retinitis pigmentosa: 30 years follow-up. *BMJ Case Rep*. 2014;2014.
- 9- Francois J, Verriest G. Retinopathie pigmentaire unilaterale. *Ophthalmologica* 1952; 124:65-87.
- 10- Takezawa M, Tetsuka S, Kakehashi A. Tangential vitreous traction: A possible mechanism of development of cystoid macular edema in retinitis pigmentosa. *Clin Ophthalmol* 2011;5:245-8.