

# Is foveal Avascular Zone a Prerequisite for Normal Vision?

Mehmet Ali ŞEKEROĞLU<sup>1</sup> , Sibel DOĞUZI<sup>2</sup> 

## ABSTRACT

The patients with fovea plana have greater central foveal thickness accompanying with an extreme decrease or absence of the foveal avascular zone (FAZ). We present a case of bilateral idiopathic isolated fovea plana who has been diagnosed during routine ophthalmic examination. We herein report the optical coherence tomography (OCT) and OCT angiography (OCTA) findings of the patient and discuss the association between the absence of the foveal pit on OCT and persistence of both superficial and deep capillary plexi at foveal center in OCTA; and aim to discuss the role of foveal pit and FAZ on visual acuity.

**Keywords:** Fovea plana, foveal avascular zone, optical coherence tomography angiography.

## INTRODUCTION

Fovea plana, which is defined as the anatomical lack of foveal pit on optical coherence tomography (OCT), is usually associated with some disorders such as albinism, PAX-6 gene mutation, incontinentia pigmenti, nanophthalmos, achromatopsia and retinopathy of prematurity; of most are related to decrease in visual acuity.<sup>1,2</sup> However, idiopathic isolated fovea plana is less common, and the absence of foveal pit does not necessarily result in a poor visual outcome in those patients.<sup>3</sup> We herein report the OCT and OCT angiography (OCTA) findings of a patient with bilateral idiopathic isolated fovea plana, and discuss the association between the absence of the foveal pit and the persistence of both superficial and deep capillary plexi at the foveal center, and relationship of foveal avascular zone (FAZ) with visual acuity.

## Case Report

A-45-year old man, who has no past history of systemic and ophthalmic disorders besides myopia, admitted to our outpatient clinic for routine ophthalmological examination. His best corrected visual acuity was 20/20 on both eyes with -1.0 D myopic correction. There was no history of any ocular or systemic diseases, and there was no history of prematurity. Anterior segments were

unremarkable on slit-lamp biomicroscopy and intraocular pressure was within normal limits and there was blunted foveal reflex bilaterally. Spectral-domain OCT (Spectralis OCT, Heidelberg, Germany) revealed flattening of the foveal contour with loss of the foveal pit bilaterally. (Figure 1) There was persistence of all inner retinal layers in both eyes throughout the central retina including where the foveal pit was expected to be. XR Avanti AngioVue (Optovue, Fremont, California, USA) was used for OCTA image acquisition and revealed that small capillaries from the superficial and deep retinal plexus crossing the midline, resulting in an absent FAZ. (Figure 2, 3)

## DISCUSSION

The fovea, which is directly related to visual acuity, is a unique part of retina exclusively containing cones with elongated outer segments and an underlying capillary free region. Fovea plana, which was formerly termed as a misnomer, foveal hypoplasia, is the anatomical lack of foveal pit, and usually associated with some ocular disorders such as albinism, PAX-6 gene mutation, incontinentia pigmenti, nanophthalmos, achromatopsia and retinopathy of prematurity.<sup>3</sup> It was also reported that patients with threshold retinopathy of prematurity who had been treated with transscleral diode laser had a significantly

1- MD, Associate Professor of Ophthalmology, Ulucanlar Eye Training and Research Hospital, Ankara, Turkey

Received: 23.09.2021

Accepted: 24.10.2021

Ret-Vit 2021; 397-399

DOI: 10.37845/ret.vit.2021.30.68

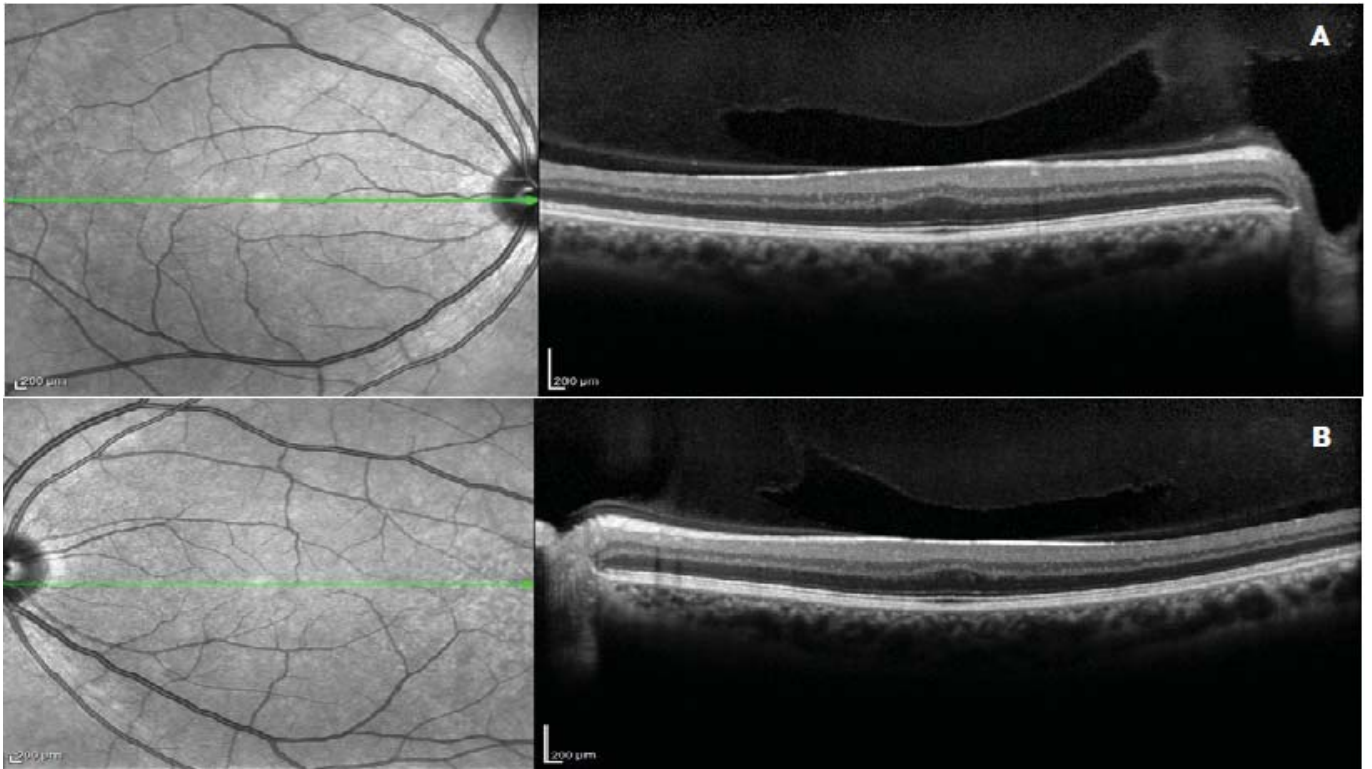
Correspondence Address:

Mehmet Ali Şekeroğlu

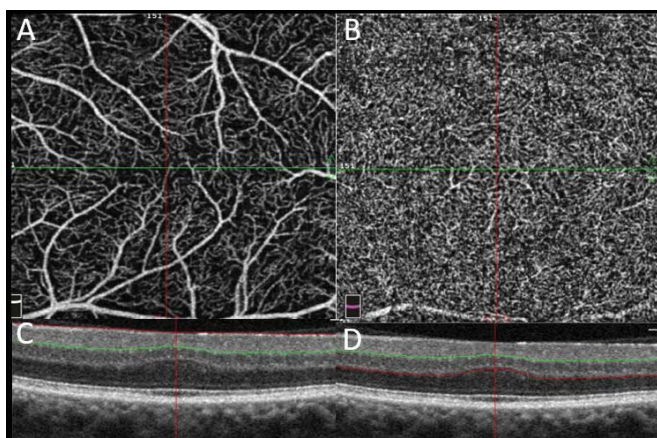
Ulucanlar Eye Training and Research Hospital, Altindag, Ankara, Turkey

Phone: +90 312 220 5113

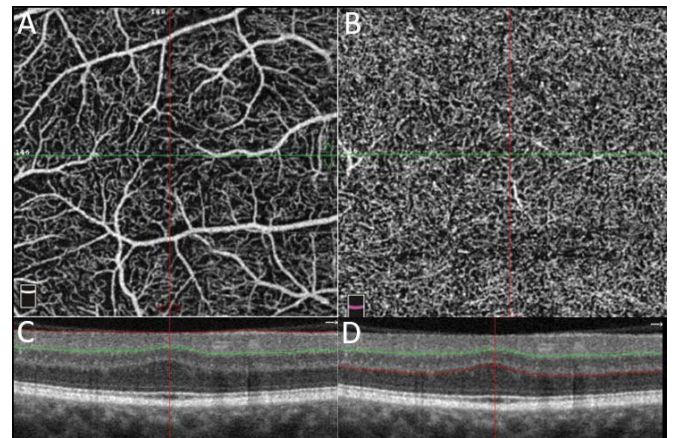
E-mail: msekeroglu@yahoo.com



**Figure 1:** Optical coherence tomography images of the (A) right and the (B) left eyes demonstrating absence of foveal pit.



**Figure 2:** Optical coherence tomography angiography (OCTA) of the right eye (A) 3x3 mm scan of the superficial capillary plexus showing that the superficial retinal capillaries crossing the foveal center (B) 3x3 mm scan of the deep capillary plexus showing that the deep retinal vessels extending into the foveal center (C) Corresponding B-scan OCT image displays the level of the superficial retinal OCTA (D) Corresponding B-scan OCT image displays the level of the deep retinal OCTA.



**Figure 3:** Optical coherence tomography angiography (OCTA) of the left eye (A) 3x3 mm scan of the superficial capillary plexus showing that the superficial retinal capillaries crossing the foveal center (B) 3x3 mm scan of the deep capillary plexus showing that the deep retinal vessels extending into the foveal center (C) Corresponding B-scan OCT image displays the level of the superficial retinal OCTA (D) Corresponding B-scan OCT image displays the level of the deep retinal OCTA.

increased macular thickness and higher incidence of absence of foveal depression with decreased visual acuity.<sup>2</sup> We herein report a patient with bilateral idiopathic isolated fovea plana who lacks foveal pit on OCT and FAZ on OCTA but still retained good visual acuity. The abnormal

development of the foveal pit has been reported to be related to the absence or reduction of FAZ.<sup>4</sup> The patient reported here provides clear evidence that the absence of FAZ does not necessarily result in disruption to other developmental processes within the foveal area. The

presence of fovea plana has been reported in up to 3% of children with normal visual acuity.<sup>5</sup>

Samara et al. proposed that OCTA provides a non-invasive method to measure FAZ in a normal population and concluded that FAZ area correlate inversely with foveal thickness.<sup>6</sup> Dubis et al. used adaptive optics scanning laser ophthalmoscope to study the correlation between foveal pit morphology and FAZ area; and found a correlation between foveal pit depth and FAZ area.<sup>7</sup> These results are in accordance with the finding of small FAZ in preterm infants as they are known to have significantly greater CMT when compared to full-term infants.<sup>8</sup> Correlation of FAZ area with increased central macular thickness and decreased foveal pit depth is in agreement with our patient. The change in FAZ size with changing retinal thickness was explained by the developmental model of the primate fovea by Springer and Hendrickson.<sup>9,10</sup> They suggested that once the FAZ is formed at 24 to 25 week of gestation, the foveal pit progressively deepens under the effect of intraocular pressure. Afterwards, there is migration of inner retinal layers away from the foveal center, migration of the cone photoreceptors into the foveal center, and elongation of the photoreceptors with ongoing axial growth. Absence of FAZ in our patient with fovea plana supports the developmental models in which FAZ size is interrelated with the structure of the fovea.

Marmor et al. showed that foveal cone specialization, represented on OCT by the lengthening of the outer segment at the fovea, can be preserved even in the absence of a foveal pit and concluded that a foveal pit is not required for foveal cone specialization.<sup>3</sup> They also demonstrated that central multifocal electroretinogram (mfERG) responses were normal in patients with fovea plana. Contrary, McTrusty et al. reported multifocal ERG recordings of a patient with fovea plana which showed a slightly reduced central peak.<sup>11</sup> Our patient showed a normal outer retina on OCT with thickening of the outer segments of the photoreceptors and the outer nuclear layer, but he lacked a foveal pit due to a possible failure of centrifugal migration of the inner retinal layers. We also found an incomplete development of the foveal vascular pattern, showing an absence of the FAZ with preservation of the normal fusion of the SCP and DCP at the fovea. So, neither a foveal pit nor FAZ is critical for preservation of a good visual acuity.

In conclusion, we report a case of idiopathic isolated fovea plana and absent FAZ with preserved visual function which confirms that fovea plana is a benign condition not requiring any intervention despite the presence of gross

anatomical change at the fovea. Future studies related to visual acuity and some other visual function tests such as contrast sensitivity depending on the FAZ area will be interesting.

**Conflict of Interest:** No conflict of interest was declared by the authors.

**Financial Disclosure:** The authors declared that this study received no financial support.

## REFERENCES

1. Thomas MG, Kumar A, Mohammad S, et al. Structural grading of foveal hypoplasia using spectral-domain optical coherence tomography a predictor of visual acuity? *Ophthalmology*. 2011;118:1653-1660.
2. Sayman Muslubas I, Karacorlu M, Hocaoglu M, et al. Retinal and choroidal thickness in children with a history of retinopathy of prematurity and transscleral diode laser treatment. *Eur J Ophthalmol*. 2017;27:190-195.
3. Marmor MF, Choi SS, Zawadzki RJ, et al. Visual insignificance of the foveal pit: reassessment of foveal hypoplasia as fovea plana. *Arch Ophthalmol*. 2008;126:907-913.
4. Kaidonis G, Silva RA, Sanislo SR, et al. The superficial and deep retinal capillary plexus in cases of fovea plana imaged by spectral-domain optical coherence tomography angiography. *Am J Ophthalmol Case Rep*. 2016;6:41-44.
5. Noval S, Freedman SF, Asrani S, et al. Incidence of fovea plana in normal children. *J AAPOS*. 2014;18:471-475.
6. Samara WA, Say EA, Khoo CT, et al. Correlation of foveal avascular zone size with foveal morphology in normal eyes using optical coherence tomography angiography. *Retina*. 2015 ;35:2188-2195.
7. Dubis AM, Hansen BR, Cooper RF, et al. Relationship between the foveal avascular zone and foveal pit morphology. *Invest Ophthalmol Vis Sci*. 2012;53:1628-1636.
8. Ecsedy M, Szamosi A, Karkó C, et al. A comparison of macular structure imaged by optical coherence tomography in preterm and full-term children. *Invest Ophthalmol Vis Sci*. 2007;48:5207-5211.
9. Springer AD, Hendrickson AE. Development of the primate area of high acuity. 1. Use of finite element analysis models to identify mechanical variables affecting pit formation. *Vis Neurosci*. 2004;21:53-62.
10. Springer AD, Hendrickson AE. Development of the primate area of high acuity, 3: temporal relationships between pit formation, retinal elongation and cone packing. *Vis Neurosci*. 2005;22:171-185.
11. McTrusty AD, McCulloch DL, Strang NC, et al. Idiopathic, isolated fovea plana with bilateral off-centre multifocal ERGs. *Doc Ophthalmol*. 2013;126:171-176.