

# How do vascular changes in retinitis pigmentosa affect the optical disc?

Fatma Busra Altas<sup>1</sup>, Sibel Doguizi<sup>2</sup>, Mehmet Ali Sekeroglu<sup>3</sup>

## ABSTRACT

**Purpose:** To investigate how the anatomical, vascular and functional structure of the optic nerve is affected in patients with retinitis pigmentosa (RP) and to compare the data obtained with healthy volunteers.

**Materials and Methods:** This cross-sectional, comparative clinical study included 25 eyes of 25 RP cases and 25 eyes of 25 healthy volunteers. After the routine ophthalmological examination, optical coherence tomography angiography (OCTA) and pattern electroretinography (pERG) examinations were performed.

**Results:** In the optic nerve head retinal nerve fiber layer (RNFL) thickness analysis, the thickness of lower temporal quadrant and mean RNFL thickness values were found to be significantly lower in the patient group when compared to the control group (respectively;  $p=0.001$ ;  $p=0.003$ ). In pERG analysis, it was found that there was a prolongation in implicit time and a decrease in wave amplitudes were detected in P50 and N95 waves in patients with RP ( $p<0.05$  for all values). Radial peripapillary capillary (RPC) mesh vascular density (VD) was significantly lower in all quadrants in the RP group ( $p<0.001$ ). A correlation was found between best corrected visual acuity (BCVA) and upper nasal quadrant RNFL thickness.

**Conclusion:** In RP patients, the vascular changes can cause optic nerve damage and decrease in BCVA. To identify changes in both vascular and nerve fiber structures around the disc using OCTA may contribute to the prediction of the prognosis and follow-up of the disease. The limited evaluable wave formation in the pERG test suggests that pERG does not provide clear results for functional evaluation in RP.

**Keywords:** Optic Disc, Optical Coherence Tomography Angiography, Pattern Electroretinography, Retinal Nerve Fiber Thickness, Retinitis Pigmentosa

## INTRODUCTION

Retinitis Pigmentosa denominates a group of degenerative retinal diseases where the rod photoreceptors are affected initially; followed by cone photoreceptors involvement, which leads to various clinical presentations that can result in blindness. It is estimated that RP affects more than 1.5 million people worldwide, with an average prevalence of 1 in 4000.<sup>1,2</sup> Symptoms, which initially present with difficulty in adjustment to darkness, progresses to night blindness, mid-peripheral scotomas in the visual field, peripheral visual field loss, tunnel vision, and loss of central vision. Fundus examination reveals typical signs of the disease including pigmentary bone spicules, waxy pallor of optic

disc, vascular attenuation, and vascular sheathing.<sup>3</sup> The severity and clinical course of the disease are influenced by the genetic inheritance pattern. The X-linked form represents the most severe presentation while the best prognosis is observed in autosomal dominant inheritance. The most common inheritance pattern is autosomal recessive; however, mitochondrial inheritance can be seen and sporadic cases can also occur.<sup>4</sup>

In RP, owing to underlying genetic mutations, the synthesis of proteins playing a role in important pathways such as cell structure and intercellular communication is disrupted. The process, starting with the apoptosis of rods and cones,

1- MD, Etlik City Hospital, Ophthalmology Department, Ankara, Türkiye

2- MD, Assoc. Prof., Ulucanlar Eye Training and Research Hospital, Ankara, Türkiye

3- MD, Prof., Ulucanlar Eye Training and Research Hospital, Ankara, Türkiye

Received: 01.08.2023

Accepted: 09.10.2023

*J Ret-Vit* 2024; 33: 19-24

DOI: 10.37845/ret.vit.2024.33.4

Correspondence Address:

Fatma Busra Altas  
Etlik City Hospital, Ophthalmology Department, Ankara, Türkiye

Phone:

E-mail: fbusraaltas@gmail.com

continues with the involvement and damage of retinal pigment epithelium (RPE) cells and glial cells. The RPE migration for retinal repair and clustering around retinal vessels result in damage to vascular structures, ischemia, and cell damage. The ischemia also affects ganglion cells. In RP, optic nerve changes may be related to ischemia and neural remodeling due to the proliferation of Müller cells. These changes can manifest as waxy pallor of optic disc (OD) or OD drusen.<sup>5,6</sup>

In the study, we aimed to investigate the relationship between structural changes in the OD and vascular factors in RP using Optical Coherence Tomography Angiography (OCTA) which enables a non-invasive and highly reproducible method in the examination the retinal vascular structure without need for contrast agents. OCTA allows us to evaluate retinal and choroidal vascular structures by layers while providing objective data regarding peripapillary vascular density and RNFL thickness.<sup>7</sup>

Pattern ERG relies on assessment of functions of macula and optic nerve by specific stimulation of ganglion cells. The full-field ERG used in RP diagnosis assesses whole retina while specific assessment of macula and OD by pERG can help to assess areas considered to be affected lately in RP and monitor the progression of the disease in a wider angle. In pERG, no pupil dilation was performed and the duration of pERG is shorter than ffERG. In our study, we aimed to provide novel insights to follow-up RP and a new perspective by comparing functional data obtained using pERG and structural data obtained using OCTA.

## MATERIAL AND METHOD

### 1. Patient Selection

This cross-sectional, comparative clinical study included 25 patients and 25 healthy volunteers (aged 20-50 years) who presented to the Ulucanlar Eye Training and Research Hospital, Health Sciences University between January 2019 and December 2019 and diagnosed with retinitis pigmentosa (RP) based on clinical and ffERG findings. The study was designed in accordance with tenets of Helsinki Declaration and approved by the Ethics Committee of the Health Sciences University Ankara Numune Training and Research Hospital. Exclusion criteria included syndromic-atypical RP cases; advanced RP patients with EIDGK (Early Treatment Diabetic Retinopathy Study Chart) less than 1.0 LogMAR; those with a previous history of ocular surgery or trauma; patients with conditions which affect optic nerve such as glaucoma or neurological diseases

involving visual pathways; those with other eye diseases such as uveitis, retinal vascular diseases; patients with spherical refractive error of  $\pm 6$  diopters and cylindrical refractive error  $\geq 2$  diopters; patients with nystagmus leading problems in fixation, and those with opacities influencing on image quality.

### 2. Study Execution and Assessment

The patients and controls underwent detailed ophthalmological examinations including BCVA by LogMAR chart, intraocular pressure measurement with tonometry, anterior segment, and dilated fundus examination; followed by pERG and OCTA imaging studies.

#### pERG Measurement

The pattern electroretinogram (pERG) recording was performed by same technician in a room isolated from magnetic fields and sound, using the Metrovision Monpack One device (Mon2014D, Metrovision, France) with HK loop electrodes, following the standards of the International Society For Clinical Electrophysiology of Vision (ISCEV). The procedure was carried out under topical anesthesia, without pupil dilation, and refractive correction was performed, if necessary, according to the appropriate test distance. After electrode placement, pERG recording was performed in the patient looking at the fixation point in the middle of the moving checkerboard patterns on the screen placed at one meter distance. The contrast between black and white squares was 95% while the average brightness was 80 cd/m<sup>2</sup>. During the test, technician observed whether patients kept their eyes open and complied with the requirements of the test. Amplitude and implicit time values for N35, P50, and N95 wave patterns were automatically calculated. During pERG, the patients failed to cooperate, those unable to maintain sufficient fixation due to low visual acuity, and individuals with similar conditions that could lead to a decrease in reliability in the wave pattern were excluded from the study.

#### OCTA Measurement

After the pERG measurement, OCTA imaging was performed using AngioVue, RTVue XR Avanti SD-OCT (Optovue, Fremont, CA, USA) device by the same experienced technician in a similar time frame (14:00-15:00) and under similar environmental conditions following pupil dilation with 1% tropicamide. In the software (Optovue, Version 2015.100.0.35) 6x6 mm image

option was preferred for macular analyses. Patients with low image quality for OCTA (signal strength index <6/10), patients with visual impairment and limited fixation, and those with artifacts affecting structural imaging were excluded from the study.

All measurements were conducted by the same experienced technician under consistent room conditions.

### 3. Statistical Analysis

The research data were transferred into electronic media and analyzed using SPSS (Statistical Package for Social Sciences) for Windows 22.0 (SPSS Inc, Chicago, IL). Descriptive statistics were presented as mean ± SD (minimum-maximum), frequency distribution, and percentage. The Pearson Chi-Square test was used to assess categorical variables. The normal distribution of variables was examined visually (histograms and probability plots) and analytically (Shapiro-Wilk Test). For variables with normal distribution, the Student’s t test was used for comparisons between two independent groups while and the Mann-Whitney U test was used to compare variables with skewed distribution. The relationship between variables was assessed using the Spearman's

correlation test. The correlation coefficient between 0-0.25 was considered as "weak," while 0.26-0.50 as "moderate," 0.51-0.75 as "strong," and 0.76-1.00 as "very strong." A p value <0.05 was considered as statistically significant.

### RESULTS

In the study, overall 50 eyes from 50 individuals were examined, including 25 patients diagnosed with RP (10 females, 15 males) and 25 healthy controls (11 females, 14 males), each contributing one eye. In the study, the LogMAR (Logarithm of the Minimum Angle of Resolution) values were significantly lower in the eyes diagnosed with RP than those in healthy control eyes (p<0.001). No statistically significant differences were found in age, gender, and intraocular pressure between the RP and control groups (p>0.05) (Table 1). In the RP group, the inferior temporal quadrant RNFL value and the mean RNFL value were significantly lower than those in the control group (p=0.001; p=0.003, respectively). There was no statistically significant difference in RNFL values in other quadrants (p>0.05) (Figure 1). In all quadrants and layers, RPK vascular density was significantly lower in the RP group (p<0.001) (Table 2). In the RP group, the

**Table 1:** Distribution of age, gender, BCVA and intraocular pressure between groups (mean ± standard deviation and significance levels). No significant difference was observed in age, gender and IOP between groups while BCVA was significantly lower in RP group.

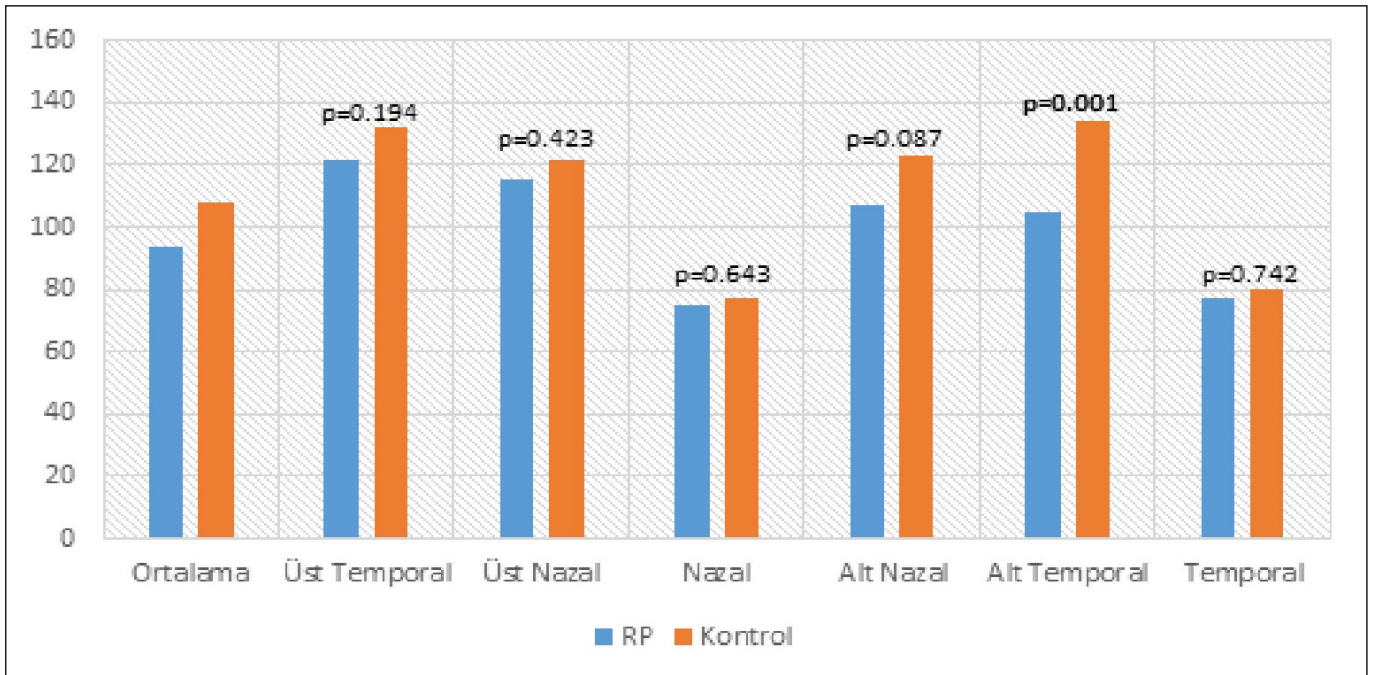
	Retinitis Pigmentosa (n=25)	Control (n=25)	p
Age (years)	37.9±9.2 (25-56)	33.6±8.5 (23-50)	0.107 <sup>a</sup>
<b>Gender</b>			
Male	15 (60.0)	14 (56.0)	0.774 <sup>b</sup>
Female	10 (40.0)	11 (44.0)	
Visual Acuity (LogMAR)	0.25±0.15 (0-0.52)	0.02±0.04 (0-0.10)	<0.001 <sup>***</sup>
Intraocular pressure (mmHg)	16.3±2.2 (12-21)	15.6±2.3 (11-20)	0.291 <sup>c</sup>

Categorical variables are presented as count (column percentage)”, continuous variables as mean ± standard deviation (minimum-maximum; n: Göz sayısı; <sup>a</sup>Mann-Whitney U Test; <sup>b</sup>Chi-square test; <sup>c</sup>Student’s t test; \*p<0.05; \*\*p<0.01

**Table 2:** Distribution of RPC vascular network density. There was a significant decrease in RPC vascular network density.

		Retinitis Pigmentosa (n=25)	Control (n=25)	p <sup>a</sup>
		Mean±SD (min-max)	Mean±SD (min-max)	
<b>Radial peripapillary capillary density (%)</b>	Full-field	48.3±5.5 (35.5-57.5)	54.8±3.0 (50.1-62.6)	<0.001 <sup>**</sup>
	Superior	48.3±6.0 (34.7-59.8)	55.2±3.9 (49.6-69.0)	<0.001 <sup>**</sup>
	Inferior	48.1±5.1 (36.2-56.8)	54.4±2.7 (50.7-61.6)	<0.001 <sup>**</sup>

n: number of eyes; SD: Standard deviation; <sup>a</sup>Mann-Whitney U test; \*p<0.05; \*\*p<0.01



**Figure 1:** Distribution of RNFL measurements between study groups. It was seen that RNFL was thinner in the RP group. The difference was significant in mean values and inferior temporal RNFL thickness.

implicit times for N35, P50, and were significantly higher while the P50 and N95 amplitudes were significantly lower when compared to the control group ( $p < 0.05$ ) while there was no statistically significant difference in N35 amplitude ( $p = 0.332$ ). In the RP group, a negative and moderately significant correlation was found between LogMAR and the superior nasal quadrant RNFL value ( $r = -0.40$ ;  $p = 0.046$ ) while no significant correlation was observed between RNFL values for other quadrants and the mean RNFL value ( $p > 0.05$ ). There was no correlation between BCVA and RPC network vascular density in the RP group. No statistically significant relationship was found between LogMAR values and pERG values in the examined eyes ( $p > 0.05$ ). In RP eyes, a positive and moderately significant correlation was found between the vascular density measurement of the inferior quadrant of the RPC network and the mean RNFL value ( $r = 0.43$ ;  $p = 0.033$ ) while no significant correlation was found between RNFL thickness in other quadrants and RPC vascular density measurements ( $p > 0.05$ ).

## DISCUSSION

In Retinitis Pigmentosa, cone cells remain unaffected until the advanced stages, preserving central vision provided by the macula. Ganglion cells and their axons are need to be intact for the healthy transduction of signals from cone cells. At this point, ganglion cells have become the focus of RP treatment. Retinal prostheses sending electrical signals

to ganglion cells have been used in experimental studies; and they have been applied to over 500 patients worldwide so far.<sup>8</sup> To predict the success of methods developed for RP treatment, it is necessary to identify the healthy structures in the existing retina. In light of these developments, the examination of inner layers of the retina including ganglion cells, RNFL, and vascular structures has become even more crucial.

The pallor of the optic disc (OD), one of the clinical triads of RP, does not always signify optic atrophy because inner retinal layers are preserved until the advanced stages. The pallor of OD may be attributed to general vascular attenuation, causing the natural pink color of the optic nerve to fade due to reduced reflectivity of retinal and disc circulation, and/or it may be related to gliosis triggered by the degeneration process starting from the outer layers of the retina.<sup>9,10</sup> Glial cell proliferation leads to thickening in the RNFL while thinning occurs due to axonal loss resulting from the degeneration of ganglion cells.<sup>11,12</sup>

In the study including 50 eyes of 30 patients, Anastasakis et al. it was found that there was thinning in 18 eyes and thickening in 21 eyes in the RNFL thickness analysis and that the thinning was predominantly detected in the inferior and nasal quadrants while thickening was observed in the temporal and superior quadrants.<sup>13</sup> In a study, Oishi et al. investigated 137 eyes of 137 RP patients aged between 20 and 80 (mean age 50) and reported that RNFL was thicker



in younger ages while it was thinner than expected in advanced ages. Authors concluded that age-related RNFL reduction in RP patients is faster (8.3  $\mu\text{m}/\text{decade}$ ) when compared to the normal population.<sup>14</sup> The mean RNFL thickness was reported as 104.1  $\mu\text{m}$  by Oishi et al. and 119.69  $\mu\text{m}$  by Anastasakis et al., indicating no significant difference in RNFL thickness between RP patients and healthy individuals.<sup>13,14</sup> In their study, Walia et al. found that 10 (40%) of 25 RP patients showed thinning in RNFL in  $\geq 2$  quadrants, affecting mainly the nasal, superior, and inferior quadrants while the temporal quadrant was preserved.<sup>11</sup> In our study, we found a significant decrease in the mean RNFL thickness (93.7  $\mu\text{m}$ ) and that the thickness in the lower temporal quadrant (105.1  $\mu\text{m}$ ) was significantly lower in the RP group compared to the control group. When the minimum and maximum values were assessed in the thickness analysis of all quadrants in all subjects, higher values were observed in the RP group compared to the control group; however, we found that the all mean values were lower in the RP group than in the control group. Additionally, the significant correlation found between the BCVA and the RNFL thickness in the upper nasal quadrant in our study was consistent with previous studies indicating thinning is more prominent in the upper and nasal quadrants.<sup>11-13</sup> No correlation was found between BCVA and the thickness of other quadrants. Oishi et al. and Walia et al. also reported no correlation between RNFL and BCVA.<sup>8-14</sup>

In our study, we observed a statistically significant decrease in the RP group compared to the control group when examining RPC vascular density. In their study, Torres et al. estimated the diameters of the first and second branches of arteries and veins in the area within 1.5 disc diameters around the optic disc using a computer software called Retinal Vessel Analyzer (RVA; IMEDOS Systems UG, Jena, Germany) and found a significant narrowing in the RP group compared to the control group.<sup>15</sup> Mastropasqua et al. evaluated RPC vessel density in 11 eyes of 11 RP patients and 16 eyes of 16 healthy volunteers using OCTA. They found a significant decrease in peripapillary vessel density in the RP group compared to the control group (52.5 $\pm$ 0.5 vs. 57.2 $\pm$ 5.1;  $p=0.011$ ). Additionally, they found a significant reduction in peripapillary RNFL in the RP group (85.9 $\pm$ 20.4  $\mu\text{m}$  in RP patients and 104.0 $\pm$ 6.4  $\mu\text{m}$  in the control group;  $p=0.002$ ). They concluded that there was a correlation between RPC vessel density and RNFL thickness.<sup>16</sup>

To understand the reflection of the structural changes observed in the functions of ganglion cells, we performed

pERG) which is not routinely used in RP and provides more specific information by measuring the functions of ganglion cells in the macula and optic disc regions of the retina. We examined the reflections of trans-neuronal degeneration of ganglion cells and nerve fiber atrophy resulting from photoreceptor damage in pERG. In their study, Janaky et al. included 106 eyes of 53 RP patients with high BCVA while excluding patients with advanced or terminal RP. Authors pERG and VEP were used to assess patients and found that there was measurable waves in only 17 patients in the pERG analyses and that no patient showed a normal pERG response.<sup>17</sup> In our study, we found that the amplitudes of P50 and N95 waves were decreased in the patient group with prolonged implicit times. In some patients, pERG waves were very vague, which could not be detected. The inconsistent pattern may be explained by the presence of very subtle changes that cannot be detected with structural tests in patients or the onset of functional losses before structural changes in some patients.<sup>18-19</sup> Although our patient group had better BCVA values than those in the previous studies, the finding that pERG waves were subtle without between BCVA and pERG led us to the conclusion that pERG may not be very beneficial for assessing the function of ganglion cells in RP. Additionally, this may be related to small size which may lead failure to obtain significant differences in pERG amplitudes. In summary, we believe that further studies with a larger number of patients are needed to determine the usefulness of pERG in RP.

Although the primary pathology is in photoreceptors in RP, vascular changes and losses in ganglion cells affect the course and prognosis of the disease. In our study, we identified a positive correlation between the RPC vascular density in the inferior quadrant and RNFL thickness. Additionally, we found a negative correlation between RNFL thickness and BCVA. Given that the patients were mostly from a young population and had better BCVA values in our study, it think that more significant relationships and stronger correlations could be identified when our sample group is expanded to include older patients with advanced RP.

## REFERENCES

1. Tsang SH, Sharma T. Retinitis Pigmentosa (Non-syndromic). *Adv Exp Med Biol* 2018;1085:125-30. [https://doi.org/10.1007/978-3-319-95046-4\\_25](https://doi.org/10.1007/978-3-319-95046-4_25)
2. Rivolta C, Sharon D, DeAngelis MM, et al. Retinitis pigmentosa and allied diseases: numerous diseases, genes, and inheritance patterns. *Hum Mol Genet* 2002;11:1219-27. <https://doi.org/10.1093/hmg/11.10.1219>

3. Verbakel SK, van Huet RAC, Boon CJF, et al. Non-syndromic retinitis pigmentosa. *Prog Retin Eye Res* 2018;66:157-86. <https://doi.org/10.1016/j.preteyeres.2018.03.005>
4. Daiger SP, Sullivan LS, Bowne SJ. Genes and mutations causing retinitis pigmentosa. *Clin Genet* 2013;84:132-41. <https://doi.org/10.1111/cge.12203>
5. Puthussery T, Taylor WR. Functional changes in inner retinal neurons in animal models of photoreceptor degeneration. *Adv Exp Med Biol* 2010;664:525-32. [https://doi.org/10.1007/978-1-4419-1399-9\\_60](https://doi.org/10.1007/978-1-4419-1399-9_60)
6. Newton F, Megaw R. Mechanisms of Photoreceptor Death in Retinitis Pigmentosa. *Genes (Basel)* 2020;11:1120. <https://doi.org/10.3390/genes11101120>
7. Spaide RF, Klancnik JM, Cooney MJ. Retinal vascular layers imaged by fluorescein angiography and optical coherence tomography angiography. *JAMA Ophthalmol* 2015;133:45-50. <https://doi.org/10.1001/jamaophthalmol.2014.3616>
8. Ovando-Roche P, Georgiadis A, Smith AJ, et al. Harnessing the Potential of Human Pluripotent Stem Cells and Gene Editing for the Treatment of Retinal Degeneration. *Curr Stem Cell Rep* 2017;3:112-23. <https://doi.org/10.1007/s40778-017-0078-4>
9. Ilhan C, Citirik M. Glial proliferation and atrophy: Two poles of optic disc in patients with retinitis pigmentosa. *J Curr Ophthalmol* 2019;31:416-21. <https://doi.org/10.1016/j.joco.2019.08.002>
10. Asakawa K, Ishikawa H, Uga S, et al. Histopathological Changes of Inner Retina, Optic Disc, and Optic Nerve in Rabbit with Advanced Retinitis Pigmentosa. *Neuroophthalmology* 2016;40:286-91. <https://doi.org/10.1080/01658107.2016.1229339>
11. Walia S, Fishman GA. Retinal nerve fiber layer analysis in RP patients using Fourier-domain OCT. *Invest Ophthalmol Vis Sci* 2008;49:3525-8. <https://doi.org/10.1167/iovs.08-1842>
12. Hood DC, Lin CE, Lazow MA, et al. Thickness of receptor and post-receptor retinal layers in patients with retinitis pigmentosa measured with frequency-domain optical coherence tomography. *Invest Ophthalmol Vis Sci* 2009;50:2328-36. <https://doi.org/10.1167/iovs.08-2936>
13. Anastasakis A, Genead MA, McAnany JJ, et al. Evaluation of retinal nerve fiber layer thickness in patients with retinitis pigmentosa using spectral-domain optical coherence tomography. *Retina* 2012;32:358-63. <https://doi.org/10.1097/IAE.0b013e31821a891a>
14. Oishi A, Otani A, Sasahara M, et al. Retinal nerve fiber layer thickness in patients with retinitis pigmentosa. *Eye (Lond)* 2009;23:561-6. <https://doi.org/10.1038/eye.2008.63>
15. Lopez Torres LT, Türksever C, Schötzau A, et al. Peripapillary retinal vessel diameter correlates with mfERG alterations in retinitis pigmentosa. *Acta Ophthalmol* 2015;93:e527-e533. <https://doi.org/10.1111/aos.12707>
16. Mastropasqua R, Borrelli E, Agnifili L, et al. Radial Peripapillary Capillary Network in Patients with Retinitis Pigmentosa: An Optical Coherence Tomography Angiography Study. *Front Neurol* 2017;8:572. <https://doi.org/10.3389/fneur.2017.00572>
17. Janáky M, Pálffy A, Horváth G, et al. Pattern-reversal electroretinograms and visual evoked potentials in retinitis pigmentosa. *Doc Ophthalmol* 2008;117:27-36. <https://doi.org/10.1007/s10633-007-9099-0>
18. Moschos MM, Chatziralli IP, Verriopoulos G, et al. Correlation between optical coherence tomography and multifocal electroretinogram findings with visual acuity in retinitis pigmentosa. *Clin Ophthalmol* 2013;7:2073-8. <https://doi.org/10.2147/OPHTH.S50752>
19. Sugita T, Kondo M, Piao CH, et al. Correlation between macular volume and focal macular electroretinogram in patients with retinitis pigmentosa. *Invest Ophthalmol Vis Sci* 2008;49:3551-8. <https://doi.org/10.1167/iovs.08-1954>