

# Management of Choroidal Neovascularization in Pathologic Myopia: Combined Therapy

## Patolojik Miyopiye Bağlı Koroidal Neovaskülarizasyonda Kombinasyon Tedavisi

Şengül ÖZDEK<sup>1</sup>, Berrak ŞEKERYAPAN<sup>2</sup>, Feyzahan EKİCİ<sup>3</sup>, Berati HASANREİSOĞLU<sup>4</sup>

Original Article

Klinik Çalışma

### ABSTRACT

**Purpose:** To report the outcome of combined verteporfin photodynamic therapy (PDT) and intravitreal bevacizumab (IVB) for the treatment of choroidal neovascularization (CNV) due to pathologic myopia.

**Materials and Methods:** The reports of the patients with CNV secondary to pathologic myopia who received PDT and 2.5 mg of IVB were reviewed. All of the eyes were examined with optic coherence tomography and fluorescein angiography in addition to Snellen visual acuity (VA) assessment and total ophthalmologic examination both before and after treatment. An activity score (AS) was given to each lesion during all visits. Retreatments were done if the AS is at least 7 during the control visits.

**Results:** Six patients were included. The mean logMAR VA was 1.30 before treatment, 0.86 at the last visit ( $p < 0.05$ ). Mean improvement in VA was 2 (range, -2 to 4) Snellen lines. The mean AS was significantly lower than the baseline at each visit ( $p < 0.05$ ). Initial foveal thickness improved from  $394.4 \pm 222.7 \mu\text{m}$  to  $175.4 \pm 25.4 \mu\text{m}$  after the last follow-up ( $p < 0.05$ ). The mean number of PDT/patient was 1.7 and that of IVB was 2.5 during the 28 months of a mean follow-up.

**Conclusion:** The results of this study suggest that PDT combined with IVB seems to be effective in treating myopic CNV by reducing retreatment needs and improving visual acuity.

**Key Words:** Pathologic myopia, photodynamic therapy, bevacizumab, combination therapy.

### ÖZ

**Amaç:** Patolojik miyopiye bağlı koroidal neovaskülarizasyonda (KNV) verteporfinli fotodinamik tedavi (FDT) ve intravitreal bevacizumab (İVB) kombinasyon tedavisinin sonuçlarının bildirilmesi.

**Gereç ve Yöntem:** Patolojik miyopiye bağlı KNV nedeniyle FDT ve 2.5 mg İVB tedavisi alan hastaların kayıtları retrospektif olarak incelendi. Gözlerin tümü tedaviden önce ve sonra Snellen görme keskinliği değerlendirildi (GK) ve tam oftalmolojik muayeneye ek olarak optik koherens tomografi ve florescein anjiyografi ile değerlendirildi. Bütün kontrol ziyaretlerinde her lezyona bir aktivite skoru (AS) verildi. Kontrol ziyaretlerinde AS'nin en az 7 olması durumunda tekrar tedavi uygulandı.

**Bulgular:** Çalışmaya toplam 6 hasta dahil edildi. LogMAR GK tedaviden önce 1.30 iken, son kontrolde 0.86 idi ( $p < 0.05$ ). GK'de ortalama 2 (-2-4) Snellen sırası artış izlendi. AS her kontrolde başlangıçtaki değere göre anlamlı olarak düşük bulundu ( $p < 0.05$ ). Başlangıç fovea kalınlığı  $394.4 \pm 222.7 \mu\text{m}$  iken son takipteki fovea kalınlığı  $175.4 \pm 25.4 \mu\text{m}$  idi ( $p < 0.05$ ). Ortalama 28 aylık takip süresi sonunda ortalama FDT/hasta sayısı 1.7 iken İVB sayısı 2.5 idi. Tartışma: Bu çalışmanın sonuçlarına göre miyopik KNV tedavisinde FDT ve İVB kombinasyon tedavisi hem tekrar tedavi ihtiyacını azaltarak hem de görme keskinliğinde artış sağlayarak, etkili bir tedavi seçeneği gibi görülmektedir.

**Anahtar Kelimeler:** Patolojik miyopi, fotodinamik tedavi, bevacizumab, kombinasyon tedavisi.

Ret-Vit 2010;18:197-202

Geliş Tarihi : 15/06/2010

Kabul Tarihi : 07/09/2010

Received : June 15, 2010

Accepted : September , 2010

- 1- Gazi Üniversitesi, Göz Hastalıkları A.D., Ankara Doç. Dr.
- 2- Rize Üniversitesi, Göz Hastalıkları A.D., Rize, Yard. Doç. Dr.
- 3- Gazi Üniversitesi, Göz Hastalıkları A.D., Ankara, Asis.Dr.
- 4- Gazi Üniversitesi, Göz Hastalıkları A.D., Ankara, Prof. Dr.

- 1- M.D. Associate Professor, Gazi University Faculty of Medicine, Department of Ophthalmology Beşevler Ankara/TURKEY  
ÖZDEK Ş.C., sozdek@gazi.edu.tr
- 2- M.D. Asistant Professor, Rize University Faculty of Medicine, Department of Ophthalmology Rize/TURKEY  
SEKERYAPAN B., bsekeryapan@yahoo.com
- 3- M.D. Asistant, Gazi University Faculty of Medicine, Department of Ophthalmology Beşevler Ankara/TURKEY  
EKİCİ F., feyzahan@yahoo.com
- 4- M.D. Professor, Gazi University Faculty of Medicine, Department of Ophthalmology Beşevler Ankara/TURKEY  
HASANREİSOĞLU B., berate@gazi.edu.tr

**Correspondence:** M.D. Asistant Professor, Berrak SEKERYAPAN  
Rize University Faculty of Medicine, Department of Ophthalmology Rize/TURKEY

## INTRODUCTION

Pathologic myopia accounts for nearly 60% of choroidal neovascularization (CNV) cases in patients younger than 50 years of age. CNV is prevalently subfoveal and often leads to rapid vision loss in the forties. CNV is usually associated with lacquer cracks and is located between the neurosensory retina and retinal pigment epithelium.<sup>1-3</sup> Although the natural course of myopic CNV is highly variable, the long-term prognosis is poor with frequent recurrences.<sup>4</sup> Photodynamic therapy (PDT) with verteporfin is currently the main proven treatment method for CNV associated with pathologic myopia.<sup>5-9</sup> However, the benefits of treatment were limited for long-term follow-up.<sup>6, 9</sup>

Recently, an anti-VEGF drug, Bevacizumab has been suggested to be effective in treating CNV secondary to age-related macular degeneration (AMD).<sup>10-12</sup> Following the first encouraging results, several studies have demonstrated intravitreal bevacizumab (IVB) to be a promising treatment method also for CNV associated with pathologic myopia.<sup>13-19</sup>

Combination therapies for CNV originated from the idea that no single therapy addressed the multifactorial pathogenesis of the disease. The goal of therapy for CNV would be to inhibit continued neovascularization and also destroy existing CNV. Combination PDT with intravitreal triamcinolone has been suggested to improve

treatment outcomes, however combined therapy did not seem to result in better visual outcome compared with PDT monotherapy and it is associated with a high risk of causing glaucoma and cataract.<sup>20</sup> Since PDT has been shown to contribute to additional VEGF expression while destroying the existing membrane, combination of PDT with IVB may be useful in treating CNV by improving visual acuity and reducing retreatment needs.<sup>21</sup>

In the present study it was aimed to evaluate the efficacy and safety of PDT combined with intravitreal bevacizumab in CNV associated with pathologic myopia.

## MATERIALS AND METHODS

Reports of the patients with CNV secondary to pathologic myopia who were treated with combined PDT with verteporfin and 2.5 mg of IVB were reviewed retrospectively after obtaining a local ethic board approval.

Pathologic myopia was defined as an eye with a minimum refractive error of  $-6$  D or retinal signs of pathologic myopia. Eyes with idiopathic CNV, AMD or angioid streaks were excluded. All patients treated with combined PDT and IVB, regardless of previous treatment, were involved in the study.

A detailed informed consent was obtained from all patients concerning the off-label use and the potential side effects of bevacizumab. Each patient underwent best

**Table 1:** Activity Scoring System (Score: 0-14); A score of 7 or more is supposed to indicate an active lesion and deserve treatment.

PARAMETER	GRADING	SCORE
<b>CLINICAL ASSESSMENT</b> (Amount of hemorrhage associated with the lesion)	No hemorrhage	0
	Decrease	1
	Same amount/baseline	2
	Increase	3
<b>OCT*</b> Subretinal fluid / retinal thickening / PED	None	0
	Decrease	1
	Any amount at beginning/Stable	2
	Increase	3
<b>FA</b> Staining pattern	No staining/ window defect	0
	Staining of scar tissue/ serous PED	1
	Late leakage/ fibrovascular PED	2
<b>SIZE OF THE LESION*</b> (SOL in FA: mm <sup>2</sup> )	Decrease	0
	Beginning size / Stable	1
	Any increase in size	2
	<b>OBJECTIVE</b>	
<b>VISUAL ASSESSMENT**</b>	Increase	0
	Baseline/ No change	1
	Decrease	2
	<b>SUBJECTIVE</b>	
	Increase	0
	Baseline/ No change	1
Decrease	2	

FA: Fluorescein Angiography; SOL: Size Of the Lesion; OCT: Optical Coherence Tomography; PED: Pigment Epithelial Detachment.

\* 10% difference is accepted as a change.

\*\* gain or loss of one or more lines in Snellen chart is accepted as a change.

corrected visual acuity (VA) measurement with a Snellen chart, slit-lamp biomicroscopic examination of the anterior segment, and dilated funduscopy examination of the posterior pole. Additionally, color fundus photography, fluorescein angiography (FA) and OCT were carried out at the baseline visit and at the monthly follow-up visits.

PDT with verteporfin was performed according to the recommended standard procedure.<sup>22</sup> Within one week after PDT, 2.5 mg bevacizumab was administered intravitreally through the pars plana according to the standard procedures.<sup>10</sup> All patients were evaluated within 1 week of the injection and asked to call promptly in case of any pain, redness or significant decrease in vision.

A new activity scoring (AS) scheme that consists of assessment of the following parameters was developed and used for assessing the lesions (Table 1).<sup>23, 24</sup> This activity scoring primarily depends on the assessment of below mentioned findings:

- 1) The amount of hemorrhage associated with the lesion (score between 0-3),
- 2) Central foveal thickness, as determined by the amount of intra/subretinal fluid in OCT (score between 0-3),
- 3) FA staining characteristics (score between 0-2),
- 4) Size of the lesion in FA (size of the lesion; SOL) (score between 0-2),
- 5) Objective and subjective visual assessments (score between 0-2 for each).

All of these parameters were evaluated to determine the general activity score of each CNV lesion at baseline and at each visit. The main outcome measures were AS, VA and number of treatments. LogMAR equivalent was used for all visual acuity calculations. Re-treatments were given in case of an AS of 7 or more. PDT was repeated with 3 months intervals when needed and IVB alone was applied if there is need for retreatment within 3 months of the initial combined treatment.

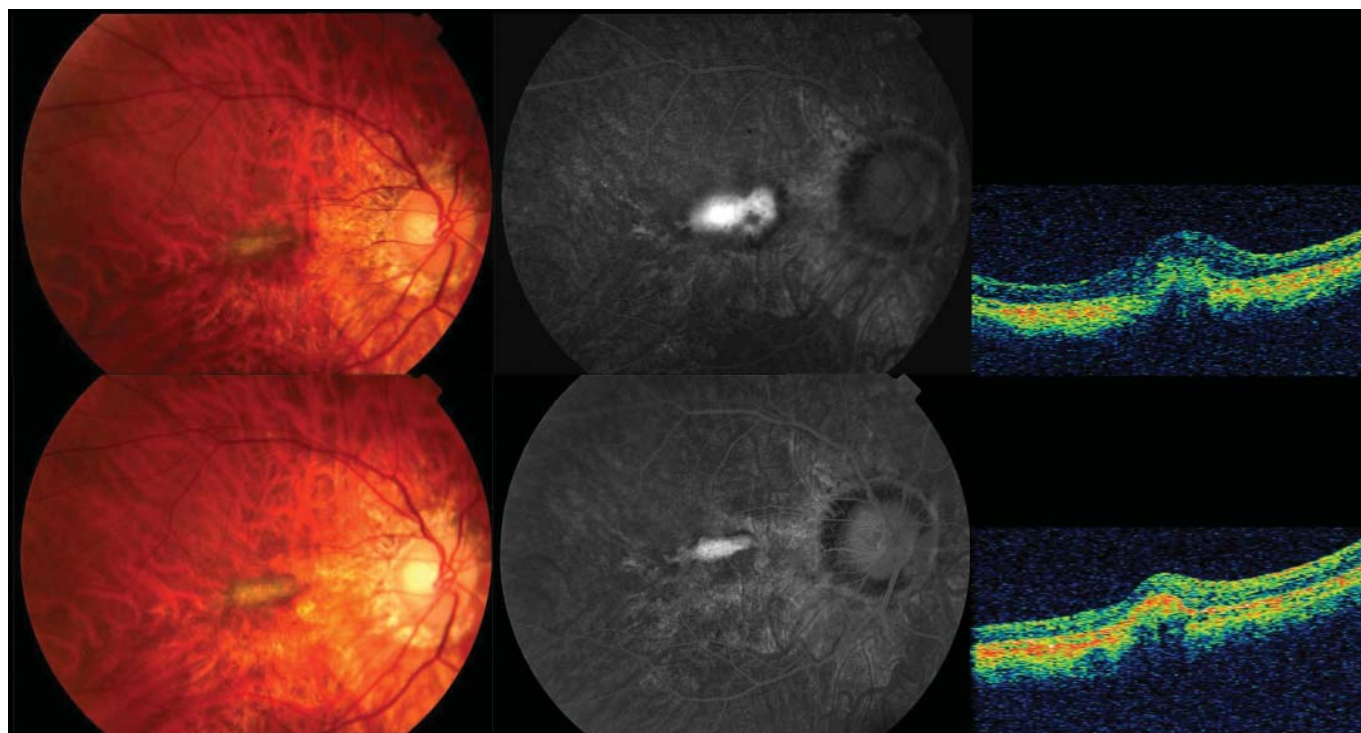
Blood pressure measurements were routinely done at all visits; any systemic adverse events including new or exacerbated hypertension, stroke or myocardial infarction were recorded, as well as ocular adverse effects including uveitis, endophthalmitis or vitreous hemorrhage.

Statistical analysis of data was carried out using the Wilcoxon test. A probability less than 5% ( $p < 0.05$ ) was considered statistically significant.

## RESULTS

Six eyes of 6 patients were treated (Table 2). The mean age was  $57.8 \pm 21.5$  years (33-85 years). Mean spherical equivalent was  $-13.3 \pm 0.57D$  ( $-13.0$  to  $-14.0D$ ). The CNV was totally classic in three eyes and predominantly classic in three eyes; 5 were subfoveal, 1 was juxtafoveal. Two eyes had undergone PDT previously. All patients were followed up for at least 15 months, with a mean follow-up time of  $28 \pm 9.6$  months (15-36 months).

All of the eyes received an initial combined PDT with 2.5 mg IVB. Two eyes received additional combination



**Figure 1:** Top row Color (left) and fluorescein angiographic (right) images showing a predominantly classical subfoveal membrane, with intraretinal fluid in the optical coherence tomography (OCT) image (right). Bottom row Color, fluorescein, and OCT images (left to right) after treatment at 27 months, with decrease in the membrane activity. The patient's initial vision improved from 1.0 logMAR to 0.5 logMAR after treatment (case 2).

**Table 2:** Patient characteristics.

Demographics			CNV		Pretreatment status				Last follow-up status			
Patient ID	Age (Years)	Eye	Lesion type	Localization	Previous treatment	VA (logMAR)	RE (diopter)	CFT ( $\mu\text{m}$ )	Months	Retreatment	VA (logMAR)	CFT ( $\mu\text{m}$ )
1	60	R	classical	subfoveal	PDTx2	1.2	-13	NA	36	-	0.4	NA
2	33	R	predominantly classical	subfoveal	None	1.0	-13	240	27	PDT+IVB	0.5	197
3	48	R	predominantly classical	subfoveal	None	1.6	-14	420	18	-	0.8	180
4	81	L	classical	juxtafoveal	None	0.5	IOL (8)	313	36	5 IVB	1.0	200
5	40	L	classical	subfoveal	PDTx1	1.9	IOL (NA)	230	15	-	1.3	160
6	85	R	predominantly classical	subfoveal	none	1.6	IOL (5)	769	36	(PDT+IVB)x3	1.1	140

CFT: Central Foveal Thickness; CNV: Choroidal Neovascular Membrane; ID: Identification Number; IOL: Intraocular Lens; IVB: Intravitreal Bevacizumab Injection; L: Left; NA: Not Available; PDT: Photodynamic Therapy; R: Right; RE: Refractive Error; VA: Visual Acuity.

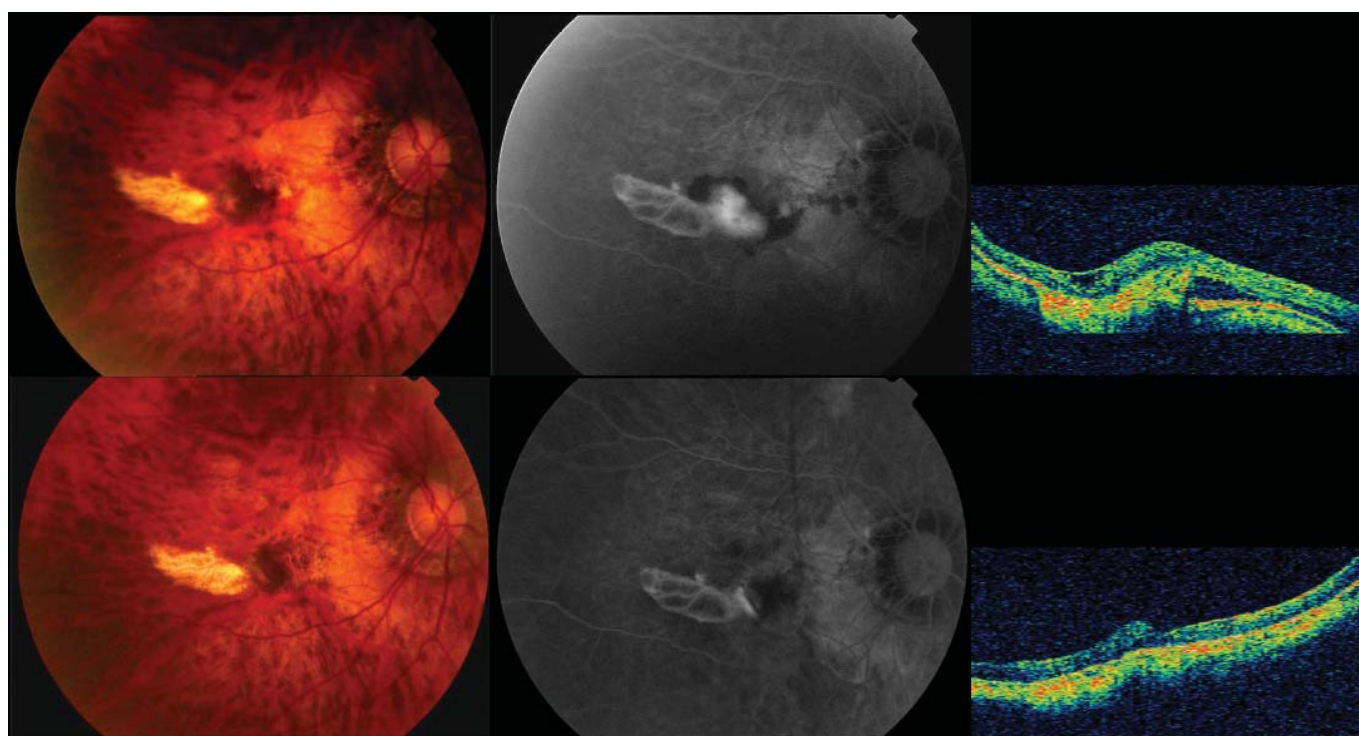
therapy and 1 eye received five additional IVB treatments alone. The mean number of PDT/patient was 1.7 and that of IVB was 2.5 during a mean follow-up of 28 months.

At baseline, the mean logMAR VA was  $1.30 \pm 0.50$  (0.50-1.90). After treatment the mean logMAR VA improved to  $1.06 \pm 0.48$  (0.50-1.90),  $1.0 \pm 0.34$  (0.50-1.40),  $0.93 \pm 0.34$  (0.50-1.30), at the 1-, 6- and 12-month follow-up, respectively. At the final follow-up the mean logMAR VA  $0.86 \pm 0.36$  was (0.40-1.30). The increase in VA was statistically significant for the 6<sup>th</sup> and 12<sup>th</sup> month and for the final follow-up compared to the baseline ( $p < 0.05$ , Wilcoxon). The mean VA improvement at the final follow-up was 2 lines. 5 eyes had visual improvement of at least 2 line after IVB, and 2 eyes had

improvement of 4 lines. 1 eye had 2 lines decrease in visual acuity due to macular scarring.

At baseline, mean AS was  $9 \pm 1.4$  (11-7). At 1<sup>st</sup> month follow-up, the score decreased to  $3.5 \pm 0.8$  (3-5) significantly ( $p = 0.026$ , Wilcoxon). Although the mean AS fluctuated at the 6<sup>th</sup> and 12<sup>th</sup> months, the values were significantly lower than the baseline ( $p < 0.05$ , Wilcoxon). At the last visit, the mean AS was  $3.3 \pm 0.5$  (3-4) ( $p < 0.05$ , Wilcoxon).

The mean central foveal thickness (CFT) at baseline was  $394.4 \pm 222.7 \mu\text{m}$  (range; 769-230  $\mu\text{m}$ ). At 1<sup>st</sup> month after treatment, the mean CFT reduced to  $165.2 \pm 15.5 \mu\text{m}$  (range; 180-140  $\mu\text{m}$ ) ( $p < 0.05$ , Wilcoxon). At 6<sup>th</sup> and 12<sup>th</sup> month follow-up, the mean CFT values were lower than baseline and at the final visit the



**Figure 2:** Top row Color (left) and fluorescein angiographic (right) images showing a predominantly classical subfoveal membrane with subretinal hemorrhage and with subretinal fluid in the optical coherence tomography (OCT) image (right). Bottom row Color, fluorescein, and OCT images (left to right) after treatment at 18 months, with the resolution of hemorrhage and a decrease in membrane activity. The patient's initial vision improved from 1.6 logMAR to 0.8 logMAR after treatment (case 3).

mean CFT was  $175.4 \pm 25.4 \mu\text{m}$  (range, 200-140  $\mu\text{m}$ ) ( $p < 0.05$ , Wilcoxon). All of the lesions were inactive without any leakage in FA at the last control visits (Figures 1, 2).

## DISCUSSION

Several studies have shown that the use of IVB for CNV secondary to pathologic myopia, led to visual improvement in addition to anatomic improvement.<sup>13-19</sup> However, the dosage and the frequency of IVB treatment for CNV secondary to pathologic myopia still remain uncertain because of the lack of sufficient prospective studies. Briefly, anti-VEGF treatment regimens are divided into two groups: injections performed as needed starting from the beginning or loading dose of monthly injections (3x) followed by additional treatments when necessary. Visual acuity and OCT findings were the main outcomes which determined further treatment need. Ikuno et al. performed 1 mg IVB in 63 eyes with myopic CNV as one injection and pro re nata (PRN) and the mean number of injection/eye was 2.4 during 12 months follow up.<sup>18</sup> Chan et al. reported 6-month results of a prospective study of 3 monthly 1.25 mg IVB injections for the treatment of myopic CNV.<sup>15</sup> This study demonstrated 90.9% of eyes had angiographic closure after 3 monthly injections of IVB and required no further treatment. However, in a similar study, Gharbiya et al. reported 40% of eyes required more than three injections during 12 months follow up.<sup>19</sup>

Combination treatment with PDT and IVB may have a beneficial synergistic effect that could reduce the need for retreatment and cyclic injections. PDT alone eradicates existing CNV and eliminates the source of VA deterioration, on the other hand, it up-regulates VEGF expression which may lead to recurrences and may limit VA benefits. The addition of anti-VEGF therapy blocks the effect of VEGF that could be over-expressed by the pathogenesis of CNV and by the effect of PDT. With this idea, several studies evaluated the efficacy and safety of PDT combined with IVB in CNV secondary to AMD. In a study, by Lazic et al., PDT and IVB combination therapy was compared with IVB monotherapy in neovascular AMD.<sup>25</sup> It was suggested that a single administration of combination therapy led to significant improvement and maintenance in visual acuity over a 3-month period than IVB monotherapy alone. In another study with CNV secondary to AMD, a single combined therapy with PDT and IVB was suggested to be sufficient for 63% of eyes within 7-month follow-up.<sup>26</sup> Recently, Han et al. reported the results of PDT and IVB combination therapy in myopic eyes with non-subfoveal lesions.<sup>27</sup>

In the present study, 3 eyes (50%) required only one single combined treatment for CNV resolution within a mean follow-up time of 28 months. Also, at the last follow-up, all lesions were angiographically inactive with

anatomical improvement without any intra/subretinal fluid in OCT.

In this study, a dose of 2.5 mg bevacizumab in 0.1 cc was used. In pathologic myopia, because of the axial elongation, the vitreous volume may be much more than that of the normal eyes, and therefore a higher dose of IVB may be required to achieve similar treatment effects. Recently, in a prospective study with 2.5 mg IVB injection for myopic CNV, the authors reported that only 28.6% of eyes required retreatment, within a follow-up period of 3 months.<sup>17</sup> Additionally, recurrent injections may increase complications such as retinal break or retinal detachment in these highly myopic eyes with long eyeballs, it is more important for these eyes to reduce the number of injections.

In the present study, an activity scoring scheme was used for evaluating the need for retreatment. This scheme has been applied in our practice to determine recurrence or reactivation of the lesion and so the need for retreatment.<sup>23</sup> Based on this scoring system, combination therapy with PDT and IVB seems to decrease the activity of myopic CNV.

This is the first paper on the results of the combination therapy (PDT and IVB) for myopic CNV with long term results. However, the retrospective nature, the small number of cases and the lack of control group for comparison are the main limitations of the study. Nevertheless, PDT combined with IVB seems to be effective in treating myopic CNV improving visual acuity with low retreatment rates.

## REFERENCES/KAYNAKLAR

- Hotchkiss ML, Fine SL.: Pathologic myopia and choroidal neovascularization. *Am J Ophthalmol.* 1981;91:177-183.
- Cohen SY, Laroche A, Leguen Y, et al.: Etiology of choroidal neovascularization in young patients. *Ophthalmology.* 1996;103:1241-1244.
- Ohno-Matsui K, Yoshida T, Futagami S, et al.: Patchy atrophy and lacquer cracks predispose to the development of choroidal neovascularization in pathological myopia. *Br J Ophthalmol.* 2003;87:570-573.
- Secrétan M, Kuhn D, Soubrane G, et al.: Long-term visual outcome of choroidal neovascularization in pathologic myopia: natural history and laser treatment. *Eur J Ophthalmol.* 1997;7:307-316
- Verteporfin in Photodynamic Therapy Study Group: Photodynamic therapy of subfoveal choroidal neovascularization in pathologic myopia with verteporfin. 1-year results of a randomized clinical trial--VIP report no. 1. *Ophthalmology.* 2001;108:841-852.
- Blinder KJ, Blumenkranz MS, Bressler NM, et al.: Verteporfin therapy of subfoveal choroidal neovascularization in pathologic myopia: 2-year results of a randomized clinical trial--VIP report no. 3. *Ophthalmology.* 2003;110:667-673.
- Gelissen F, Inhoffen W, Hermann A, et al.: Verteporfin photodynamic therapy for extrafoveal choroidal neovascularization in pathologic myopia. *Graefes Arch Clin Exp Ophthalmol.* 2004;42:926-930.
- Lam DS, Liu DT, Fan DS, et al.: Photodynamic therapy with verteporfin for juxtafoveal choroidal neovascularization secondary to pathologic myopia-1-year results of a prospective series. *Eye.* 2005;19:834-840.
- Schnurrbusch UE, Jochmann C, Wiedemann P, et al.: Quantitative assessment of the long-term effect of photodynamic therapy in patients with pathologic myopia. *Graefes Arch Clin Exp Ophthalmol.* 2005;243:829-833.

10. Rosenfeld PJ, Moshfeghi AA, Puliafito CA.: Optical coherence tomography findings after an intravitreal injection of bevacizumab (Avastin) for neovascular age-related macular degeneration. *Ophthalmic Surg Lasers Imaging*. 2005;36:331-335.
11. Avery RL, Pieramici DJ, Rabena MD, et al.: Intravitreal bevacizumab (Avastin) for neovascular age-related macular degeneration. *Ophthalmology*. 2006;113:363-372.
12. Emerson MV, Lauer AK, Flaxel CJ, et al.: Intravitreal bevacizumab (Avastin) treatment of neovascular age-related macular degeneration. *Retina*. 2007;27:439-444.
13. Yamamoto I, Rogers AH, Reichel E, et al.: Intravitreal bevacizumab (Avastin) as treatment for subfoveal choroidal neovascularization secondary to pathological myopia. *Br J Ophthalmol*. 2007;91:157-160.
14. Sakaguchi H, Ikuno Y, Gomi F, et al.: Intravitreal injection of bevacizumab for choroidal neovascularization associated with pathological myopia. *Br J Ophthalmol*. 2007;91:161-165.
15. Chan WM, Lai TY, Liu DT, et al.: Intravitreal bevacizumab (Avastin) for myopic choroidal neovascularization: six-month results of a prospective pilot study. *Ophthalmology*. 2007;114:2190-2196.
16. Hernández-Rojas ML, Quiroz-Mercado H, Dalma-Weiszhausz J, et al.: Short-term effects of intravitreal bevacizumab for subfoveal choroidal neovascularization in pathologic myopia. *Retina*. 2007;27:707-712.
17. Ruiz-Moreno JM, Gomez-Ulla F, Montero JA, et al.: Intravitreal bevacizumab to treat subfoveal choroidal neovascularization in highly myopic eyes: short-term results. *Eye*. 2009;23:334-338.
18. Ikuno Y, Sayanagi K, Soga K, et al.: Intravitreal bevacizumab for choroidal neovascularization attributable to pathological myopia: one-year results. *Am J Ophthalmol*. 2009;147:94-100.
19. Gharbiya M, Allievi F, Mazzeo L, et al.: Intravitreal bevacizumab treatment for choroidal neovascularization in pathologic myopia: 12-month results. *Am J Ophthalmol*. 2009;147:84-93.
20. Chan WM, Lai TY, Wong AL, et al.: Combined photodynamic therapy and intravitreal triamcinolone injection for the treatment of choroidal neovascularization secondary to pathological myopia: a pilot study. *Br J Ophthalmol*. 2007;91:174-179.
21. Lazic R, Gabric N.: Intravitreally administered bevacizumab (Avastin) in minimally classic and occult choroidal neovascularization secondary to age-related macular degeneration. *Graefes Arch Clin Exp Ophthalmol*. 2007;45:68-73.
22. Verteporfin Roundtable Participants. Guidelines for using verteporfin (Visudyne) in photodynamic therapy for choroidal neovascularization due to age-related macular degeneration and other causes: update. *Retina*. 2005;25:119-134.
23. Ozdek S, Hondur A, Gurelik G, et al.: Transpupillary thermotherapy for myopic choroidal neovascularization: 1-year follow-up: TTT for myopic CNV. *Int Ophthalmol*. 2005;26:127-133.
24. Ozdek S.: My way of assessment of neovascular AMD activity. When to treat? When to stop? *Ophthalmol Times Europe*, May 2009; e-pub, <http://www.oteurope.com/ophthalmologytimeseuropa/article/articledetail.jsp?ts=111809040229&id=598240>
25. Lazic R, Gabric N.: Verteporfin therapy and intravitreal bevacizumab combined and alone in choroidal neovascularization due to age-related macular degeneration. *Ophthalmology*. 2007;114:1179-1185.
26. Dhalla MS, Shah GK, Blinder KJ, et al.: Combined photodynamic therapy with verteporfin and intravitreal bevacizumab for choroidal neovascularization in age-related macular degeneration. *Retina*. 2006;26:988-993.
27. Han DP, McAllister JT, Weinberg DV, et al.: Combined intravitreal anti-VEGF and verteporfin photodynamic therapy for juxtafoveal and extrafoveal choroidal neovascularization as an alternative to laser photocoagulation. *Eye (Lond)* 2009 Jun 5.