

Central Choroidal and Macular Thickness in Healthy Turkish Subjects Measured Using Spectral-Domain Optical Coherence Tomography

Türkiye'deki Sağlıklı Bireylerde Spectral-Domain Optik Koherens Tomografi ile Santral Koroidal ve Maküler Kalınlık Ölçümü

Osman Ahmet POLAT¹, Neslihan SİNİM¹, Ayşe ÖZTÜRK ÖNER²

ABSTRACT

Purpose: The choroid plays a vital role in the pathophysiology of many diseases affecting the choroid and the retina, but adequate visualization and the certain thickness measurement of the choroid have not been possible until recently. Since 2006, a variety of spectral-domain OCT instruments have become commercially available; and *in vivo* choroidal thickness measurements are possible. In this study we examined central choroidal and macular thickness in healthy Turkish subjects using spectral-domain optical coherence tomography (SD-OCT) and aimed to reveal normal choroidal thickness to compare with pathologic conditions.

Materials and Methods: Three hundred eyes of 150 subjects with no retinal or choroidal disease and refractive error, underwent high-definition raster scanning using SD-OCT with frame enhancement software. Choroidal thickness was measured from the posterior edge of the retinal pigment epithelium to the choroid-sclera junction. Furthermore, the central foveal thickness was also measured at the same time.

Results: The mean age of the subjects was 36.8 (range, 29 to 41) years. All eyes had normal foveal contour with no retinal pathology and no abnormalities of the choroid. The visual acuity in all patients was 1.0 Snellen lines. The mean choroidal thickness at the center of the fovea was 287.6 μm (range, 241 to 313). The mean central macular thickness was 215.4 μm (range, 179 to 252).

Conclusions: The choroid is a highly vascular tissue necessitating *in vivo* imaging to accurately determine its true structure and thickness. Choroidal thickness can change in some ocular pathologies. Until recently, the information regarding choroidal thickness in normal eyes was based primarily on histological results, which do not necessarily reflect the true measurements of this dynamic tissue. Choroidal and macular thickness may vary with location and this should be considered when evaluating the choroidal and macular thickness. Improved *in vivo* visualization of the choroid and measurement of choroidal thickness using OCT is likely to improve our understanding of a variety of ophthalmic diseases in the future.

Key Words: Choroidal, thickness, Turkish, optical coherence tomography.

ÖZ

Amaç: Retina ve koroidi etkileyen pek çok hastalıkta koroid önemli rol oynar, fakat son zamanlara kadar koroidin uygun görünülmesi ve kalınlığının doğru ölçümü mümkün olmamıştır. OCT cihazları ticari olarak sunulduğundan beri, koroid kalınlığının *in vivo* ölçümü mümkün olmuştur. Bu çalışmada, Türkiye'deki sağlıklı bireylerde OCT ile santral koroidal ve makular kalınlıkların ölçülmesi ve sunulması amaçlanmıştır.

Gereç ve Yöntem: Retinal, koroidal hastalığı veya refraksiyon kusuru olmayan 150 bireyin 300 gözü SD-OCT cihazı ile tarandı. Koroid kalınlığı, retina pigment epitelinin arka sınırı ile koroid-sklera kesişimi arasındaki mesafe olarak ölçüldü. İlave olarak, santral foveal kalınlık da eş zamanlı ölçüldü.

Bulgular: Yaş ortalaması 36.8 (29-41) bulunmuştur. Tüm gözlerde foveal kontür doğaldı, retinal patoloji veya koroid anomalisi yoktu ve görme keskinlikleri Snellen eşeline göre 1.0 idi. Fovea merkezindeki ortalama koroid kalınlığı 287.6 μm (241-313) ve santral makula kalınlığı 215.4 μm (179-252) olarak bulundu.

Sonuç: Bazı göz hastalıklarında koroid kalınlığı değişebilir. Koroid ve makular kalınlık, lokalizasyona göre değişebilmektedir bu durum ölçümler değerlendirilirken göz önünde bulundurulmalıdır. OCT ile koroid dokusunun *in vivo* olarak daha iyi görüntülenmesi ve kalınlığının daha iyi ölçülmesi, gelecekte çeşitli göz hastalıklarının anlaşılmasına yardım edecektir.

Anahtar Sözcükler: Koroidal, kalınlık, türk bireyler, optik koherens tomografi.

- M.D., Erciyes University Faculty of Medicine, Department of Ophthalmology, Kayseri/TURKEY
POLAT O.A., osmanahmet@gmail.com
SİNİM N., nsinim@hotmail.com
- M.D. Associate Professor, Erciyes University Faculty of Medicine, Department of Ophthalmology, Kayseri/TURKEY
ÖZTÜRK ÖNER A., ayseozoner@gmail.com

Geliş Tarihi - Received: 25.04.2011
Kabul Tarihi - Accepted: 08.06.2012
Ret-Vit 2012;20:95-98

Yazışma Adresi / Correspondence Address: M.D. Asistant, Osman Ahmat POLAT
Erciyes University Faculty of Medicine, Department of Ophthalmology, Kayseri/TURKEY

Phone: +90 352 207 66 66
E-Mail: osmanahmet@gmail.com

INTRODUCTION

The choroid is a highly vascular tissue forming posterior uvea under the retina and pigment epithelium layers. It's a critical anatomical structure playing a critical role in blood supply of the eye especially outer retina layers.

It has functions like thermoregulation, regulating intraocular pressure by uveascleral aqueous drainage, adjustment of the position of the retina by changes in choroidal thickness, and secretion of growth factors.¹

Choroid and its thickness can be affected in many ocular diseases. Choroidal neovascular membrane, uveal effusion syndrome, central serous chorioretinopathy, Vogt-Koyanagi-Harada disease, angioid streaks, polypoidal choroidal vasculopathy are clinical pathologies can affect the choroidal thickness.¹²⁻²⁰

Therefore, it is clinically important to know *invivo* normal choroidal thickness accurately. And this will give opportunity to compare with pathological conditions. In this study we aimed to examine choroidal and macular thicknesses in healthy Turkish subjects by spectral-domain optical coherence tomography (SD-OCT).

MATERIALS AND METHODS

Three hundred eyes of 150 subjects (75 female, 75 male) who applied our outpatient clinic with no retinal or choroidal disease and without any refractive error, underwent high-definition raster scanning using SD-OCT with frame enhancement software. The choroid was imaged in the choroidal mode with the SD-OCT system.

In the choroidal mode, the signal from the retinochoroidal portion of the scanned region is enhanced relative to that in the vitreoretinal portion. Each image encompassing the fovea was obtained from 9 averaged scans. In most cases, good-quality images were obtainable, allowing choroidal thickness measurements to be performed.

All images included in this study were taken as close to the fovea as possible in order to demonstrate clear visualization of the choroid sclera interface. The choroidal thickness was defined as the distance from the outer border of the retinal pigment epithelium line to the hyperreflective line behind the large vessel layers of the choroid, which is presumed to be the choroid sclera interface.

Choroidal thickness measurements were obtained manually using the linear measurement tool perpendicular from the base of the hyperreflective retinal pigment epithelium to the choroid sclera junction. (Figure) The central foveal thickness was also measured at this time.

RESULTS

The mean age of the subjects was 36.8 (range, 29 to 41) years. All eyes had normal foveal contour with no retinal pathology and no abnormalities of the choroid. The visual acuity in all patients was 1.0 Snellen lines without any refractive correction.

The mean choroidal thickness at the center of the fovea was 287.6 μm (range, 241 to 313). The mean central macular thickness was 215.4 μm (range, 179 to 252).

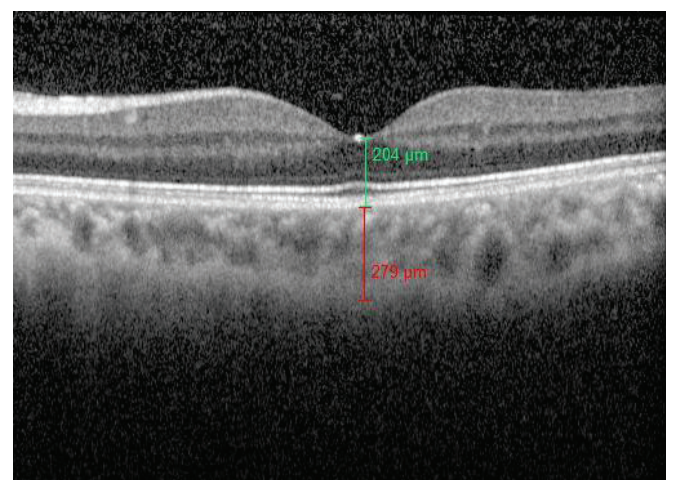
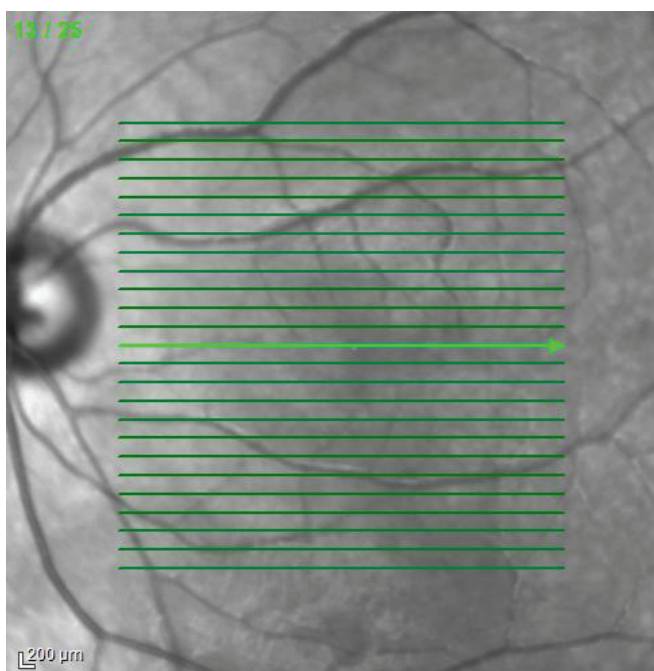


Figure: Central macular thickness is 204 μm , central choroidal thickness is 279 μm in an healthy 30 years old male subject.

DISCUSSION

Until recently, choroidal thickness assumptions were mostly based on histological techniques. The mean choroidal thickness was found to be 200 μm histologically.² However, during histological sample preparation steps, for instance the fixation, tissue loses its water content and these samples are obtained from autopsies which blood vessels collapse. Thus, this explains why histological measurements are found to be less than OCT measurements.

The other *in vivo* techniques measuring choroidal thickness like partial coherence interferometry for pediatric age group finding mean choroidal thickness 326 μm , extrapolated ocular radiofrequency velocities finding mean choroidal thickness 420 μm and optical low coherence reflectometry finding mean choroidal thickness 324 ± 71 μm have also been reported.³⁻⁵ *In vivo* choroidal thickness for rats by MRI also has been described.⁶ But there is no any other studies comparing these techniques.

McCourt et al.,⁷ showed that the mean subfoveal choroidal thickness of the 194 eyes studied was 246.59 ± 93.17 μm with a mean age of 55.50 ± 19.70 years.

Ding et al.,⁸ reported normal subfoveal choroidal thickness using enhanced depth imaging spectral-domain optical coherence tomography in healthy Chinese population for younger than 60 years age as 294.63 ± 75.90 μm and for older than 60 years age as 196.52 ± 74.42 μm . They mentioned significant negative correlation between age and choroidal thickness.

Fujimara et al.,⁹ reported mean subfoveal thickness as 265.5 ± 82.4 μm in normal Japanese eyes. Ikuno et al.,¹⁰ showed mean choroidal thicknesses as 354 ± 111 μm (range, 80-641 μm) at the fovea for healthy Japanese subjects. Their study demonstrated positive correlation with refractive error and negative correlation with both axial length and age. In our study, we found central choroidal thickness as 287.6 μm (range, 241 to 313). It is known that refractive error and age could affect the choroidal thickness measurements.

The difference among studies can be associated with the study design which in our study we only included subjects without any refraction error and the subjects under the age of 50. Yamashita et al. studied the central choroidal thickness of the right eye of 43 normal subjects measured using three different SD-OCTs: Heidelberg Spectralis-OCT (Spectralis), Cirrus HD-OCT (Cirrus), and Topcon 3D OCT-1000 Mark II (Topcon) and reported that measurements obtained with three different SD-OCTs were highly correlated and could be used interchangeably.¹¹

We conducted our study using Heidelberg Spectralis SD-OCT. The relationship between choroidal thickness and some ocular diseases have been investigated. Manjunath et al.,¹² studied choroidal thickness for age related macular degeneration patients and they concluded that the choroidal thickness can be measured by spectral-domain optical coherence tomography and variable choroidal thickness exists among patients with the clinical diagnosis of wet and dry AMD, some tending to decrease and others tend to increase and they couldn't reveal the exact relationship.

Kim et al.,¹³ compared choroidal thickness among age related macula degeneration, central serous chorioretinopathy, and polypoidal choroidal vasculopathy patients and healthy subjects. They demonstrated that the choroid was thicker in the eyes with polypoidal choroidal vasculopathy or central serous chorioretinopathy than in control or age-related maculopathy groups.¹⁴

Christini et al.,¹⁵ compared choroidal thickness between chronic glaucoma patients and healthy patients and they reported that choroid in the glaucomatous eyes showed an increase of 20% as compared with normal eyes.

Harada et al.,¹⁶ showed that for uveal effusion syndrome choroidal thickness measured with OCT was higher for patients than age matched normal individuals. Choroidal thickness changes on OCT for Vogt-Kayanagi-Harada disease and central serous chorioretinopathy have also been reported.¹⁷⁻¹⁹

Esmaeelpour et al.,²⁰ showed that type II diabetes patients have thinner choroid thickness than normal population.

There are a few publications reporting diurnal variation for the choroidal thickness. Tan et al.,²¹ found diurnal variation for the choroidal thickness with the mean amplitude of of 33.7 μm . And they concluded that the amplitude of variation varies with morning baseline CT, and is correlated with age, axial length, refractive error, and change in systolic blood pressure.

Brown et al.,²² also described diurnal variation for choroidal thickness using partial coherence interferometry which is a kind of A-scan ultrasonography. Therefore, it might be important to monitor the choroidal thickness keeping in mind that there can be diurnal variation.

As a conclusion, the choroid is a highly vascular tissue, necessitating accurate *in vivo* imaging to determine its true structure and thickness. Choroidal thickness can change in some ocular pathologies and also can be used to monitor some of these.

Choroidal and macular thickness may vary with location and this should be considered when evaluating the choroidal and macular thickness. Improved *in vivo* visualization of the choroid and the measurement of choroidal thickness using OCT is likely to improve our understanding of a variety of ophthalmic diseases in the future.

REFERENCES/KAYNAKLAR

- Nickla DL, Wallman J. The multifunctional choroid. *Prog Retin Eye Res* 2010; 29:144-68.
- Ramrattan RS, van der Schaft TL, Mooy CM, et al. Morphometric analysis of Bruch's membrane, the choriocapillaris, and the choroid in aging. *Invest Ophthalmol Vis Sci* 1994;35:2857-64.
- Coleman DJ, Luzzi FL. *In vivo* choroidal thickness measurement. *Am J Ophthalmol* 1979;88:369-75.
- Brown JS, Flitcroft DI, Ying GS, et al. *In vivo* human choroidal thickness measurements: evidence for diurnal fluctuations. *Invest Ophthalmol Vis Sci* 2009;50:5-12.
- Read SA, Collins MJ, Alonso-Caneiro D. Validation of optical low coherence reflectometry retinal and choroidal biometry. *Optom Vis Sci*. 2011;88:855-63.
- Nair G, Pardue MT, Kim M, et al. Manganese Enhanced MRI reveals multiple cellular and vascular layers in normal and degenerated retinas. *J Magn Reson Imaging* 2011;34:1422-9.
- McCourt EA, Cadena BC, Barnett CJ, et al. Measurement of subfoveal choroidal thickness using spectral domain optical coherence tomography. *Ophthalmic Surg Lasers Imaging* 2010;41:28-33.
- Ding X, Li J, Zeng J, et al. Choroidal thickness in healthy Chinese subjects. *Invest Ophthalmol Vis Sci* 2011;52:9555-60.
- Fujiwara A, Shiragami C, Shirakata Y, et al. Enhanced depth imaging spectral-domain optical coherence tomography of subfoveal choroidal thickness in normal Japanese eyes. *Jpn J Ophthalmol* 2012
- Ikuno Y, Kawaguchi K, Nouchi T, et al. Choroidal thickness in healthy Japanese subjects. *Invest Ophthalmol Vis Sci* 2010;51:2173-6.
- Yamashita T, Yamashita T, Shirasawa M, et al. Repeatability and reproducibility of subfoveal choroidal thickness in normal eyes of Japanese using different SD-OCT devices. *Invest Ophthalmol Vis Sci* 2012;53:1102-7.
- Manjunath V, Goren J, Fujimoto JG, et al. Analysis of choroidal thickness in age-related macular degeneration using spectral-domain optical coherence tomography. *Am J Ophthalmol* 2011;152:663-8.
- Kim SW, Oh J, Kwon SS, et al. Comparison of choroidal thickness among patients with healthy eyes, early age-related maculopathy, neovascular age-related macular degeneration, central serous chorioretinopathy, and polypoidal choroidal vasculopathy. *Retina* 2011;31:1904-11.
- Koizumi H, Yamagishi T, Yamazaki T, et al. Subfoveal choroidal thickness in typical age-related macular degeneration and polypoidal choroidal vasculopathy. *Graefes Arch Clin Exp Ophthalmol* 2011;249:1123-8.
- Cristini G, Cennamo G, Daponte P. Choroidal thickness in primary glaucoma. *Ophthalmologica* 1991;202:81-5.
- Harada T, Machida S, Fujiwara T, et al. Choroidal findings in idiopathic uveal effusion syndrome. *Clin Ophthalmol* 2011;5:1599-601.
- Nakai K, Gomi F, Ikuno Y, et al. Choroidal observations in Vogt-Koyanagi-Harada disease using high-penetration optical coherence tomography. *Graefes Arch Clin Exp Ophthalmol* 2012.
- Maruko I, Iida T, Sugano Y, et al. Subfoveal choroidal thickness after treatment of Vogt-Koyanagi-Harada disease. *Retina* 2011;31:510-7.
- Maruko I, Iida T, Sugano Y, et al. Subfoveal choroidal thickness in fellow eyes of patients with central serous chorioretinopathy. *Retina* 2011;31:1603-8.
- Esmaeelpour M, Považay B, Hermann B, et al. Mapping choroidal and retinal thickness variation in type 2 diabetes using three-dimensional 1060-nm optical coherence tomography. *Invest Ophthalmol Vis Sci* 2011;52:5311-6.
- Tan CS, Ouyang Y, Ruiz H, et al. Diurnal variation of choroidal thickness in normal, healthy subjects measured by spectral domain optical coherence tomography. *Invest Ophthalmol Vis Sci* 2012;53:261-6.
- Brown JS, Flitcroft DI, Ying GS, et al. *In vivo* human choroidal thickness measurements: evidence for diurnal fluctuations. *Invest Ophthalmol Vis Sci* 2009;50:5-12.