

Premacular Subhyaloid Hemorrhage Drainage by Argon Laser

Makula Önü Subhyoloid Hemarajinin Argon Laser ile Drenajı

Utku LİMON¹

ABSTRACT

Twenty-one years old healthy female admitted with sudden loss of vision in the right eye after sneezing. Best corrected visual acuity was counting fingers at 1 meter. Dilated fundus examination of the right eye revealed a large preretinal hemorrhage encompassing the fovea and inferior macula. On the second day of her presentation the patient underwent argon laser hyaloidotomy for drainage of subhyaloid hemorrhage. The day after treatment the vision was 0.7 in the right eye and improved to 1.0 six days later without any complication. Premacular subhyaloid hemorrhage can be treated by argon laser safely and optical coherence tomography (OCT) is a useful method for monitoring internal limiting membrane (ILM) and retina.

Key words: Subhyaloid hemorrhage, argon laser

ÖZ

Hapşurma sonrası 21 yaşında sağlıklı erkek bir hastada ani görme kaybı ile müracaat eden hastada semptomun preretinal hemoraji Argon Laser ile direne edilmiştir.

Key words: Subhyoloid kanama, argon lazer

INTRODUCTION

Premacular hemorrhage is a cause of profound, painless loss of vision and may occur due to valsalva retinopathy, diabetic retinopathy, vein occlusion, macroaneurysm, hematologic disorders, trauma, Terson syndrome and age related macular degeneration.¹⁻² Valsalva retinopathy usually occurs secondary to Valsalva's maneuver, a strong exhalation effort causing sudden rise in intrathoracic venous pressure, which may cause rupture of the macular vessels and premacular hemorrhage.³ There are several risk factors that may contribute to this condition like weight lifting, vomiting, physical exercise and balloon inflation.⁴

In valsalva retinopathy hemorrhage may be seen under internal limiting membrane, subhyaloid, intravitreal, subretinal or in combination of these. It has a circular shape in the beginning and latter becomes hemispherical and typically boat shaped due to the gravity.⁵

Spontaneous resorption of the blood in the subhyaloid space may be very slow and takes several months to years to resolve.⁶ Long term complications are epiretinal membrane, macular traction and retinal detachment.⁷⁻⁸ Argon laser hyaloidotomy is known as a relatively safe and effective method for draining premacular hemorrhage into the vitreous cavity.⁹ After treatment, the changes on the ILM and retina can be observed with spectralis OCT.¹⁰

In this case, a premacular subhyaloid hemorrhage treated by argon laser is reported.

CASE REPORT

A 21 years old healthy female admitted with sudden loss of vision in the central and upper part of the visual field with black shadow in front of the right eye. Her complaint started after sneezing three days ago. There was not any history of ophthalmologic and systemic disease or trauma. During

1- Uz. Dr. Ümraniye Eğitim Araştırma Hastanesi, Göz Hastalıkları Kliniği, İstanbul - TÜRKİYE

Geliş Tarihi - Received: 04.04.2016

Kabul Tarihi - Accepted: 09.04.2016

Ret-Vit 2017;26:79-82

Yazışma Adresi / Correspondence Address:

E-mail: utku_limon@hotmail.com

Phone: 0506 848 7190

examination refraction spherical equivalent was +3.25 in the right eye and -0.50 in the left eye. Visual acuity was finger counting at 1 meter in the right eye and 1.0 in the left eye. Slit lamp biomicroscopy revealed a normal anterior segment for both eyes. Intraocular pressure was 18 mmHg on the right and 16 mmHg on the left. At fundus examination of the right eye there was a semicircular, well circumscribed 4 disc diameter in size and partially dark red preretinal hemorrhage with a convex surface. It was covering the fovea and inferior macula (Fig.1). Examination of left fundus was completely normal. Systemic examination and blood pressure were normal. Platelet:367.000 μ l, WBC:8500 μ l, INR and other laboratory tests were within normal ranges. She was diagnosed as Valsalva retinopathy on the basis of the history and fundus examination. During the follow up coloured fundus photography and OCT was performed and the patient underwent argon laser hyaloidotomy. Before the procedure full pupillary dilatation was done with %0,5 tropicamid and %5 phenylephrine. A Goldmann fundus contact lens was used for focusing Argon laser beam. Five spots of argon green laser were performed at inferior margin of the hematoma on the anterior surface with a spot size of 100 μ m, exposure duration of 0.1 seconds and power of 500 mW. Then the subhyaloid blood immediately diffused to the posterior vitreus (Fig.2.) On the first post treatment day refractions spherical equivalent was +0.50 and best corrected visual acuity improved to 0.7 in the right eye. At fundus examination blood level was significantly decreased (Fig.3.). One week after treatment refractions spherical equivalent was +0.00 and best corrected visual acuity was 1.0. After one month the patients vision improved to 1.0, subhyaloid hemorrhage was completely withheld (Fig.4.) and her OCT findings were unremarkable (Fig.5.).

DISCUSSION

Valsalva retinopathy may cause preretinal hemorrhage and early treatment allows more rapid visualization as in my case.¹¹⁻¹² Treatment modalities include observation of small and extrafoveal hemorrhages, vitrectomy for refractory and longstanding cases, intravitreal gas and tissue plasminogen activator (TPA) injection and Nd:YAG or Argon laser hyaloidotomy. Nd:YAG laser hyaloidotomy is used for subhyaloid drainage in many cases in literature with energy levels ranging from 2.5 to 50 mJ with relatively good success.¹³ It is designed for anterior segment and in shallow subhyaloid hemorrhages it may cause damage to the retina. Due to its potential damage, it has been emphasized that Nd:YAG therapy can only be used in premacular hemorrhages at least 3 disc diameters in size.¹⁴ Early vitrectomy can be also the choice of treatment but after that procedure recovery time is longer than the patients with Nd:YAG or Argon laser hyaloidotomy. There are many intra and postoperative complications of vitrectomy than laser.¹⁵ TPA has been successfully used with intraocular

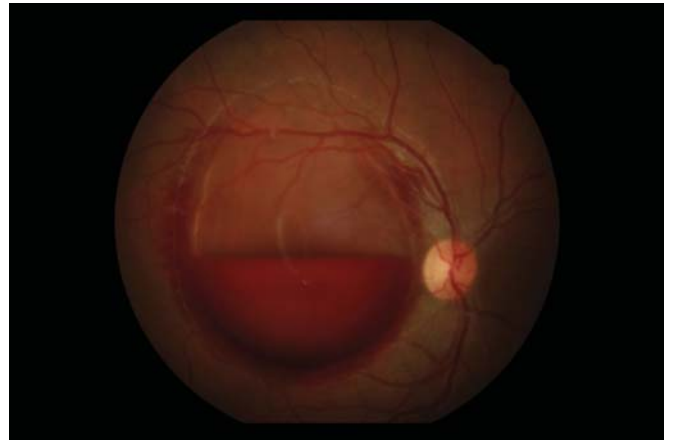

Fig. 1: Pre treatment picture.

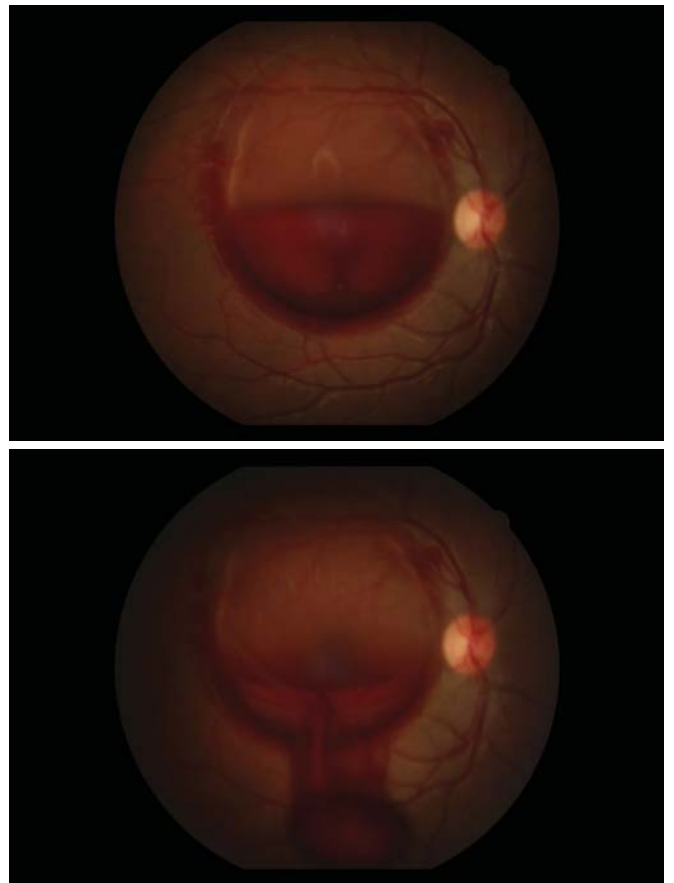


Fig. 2: Pictures during treatment.

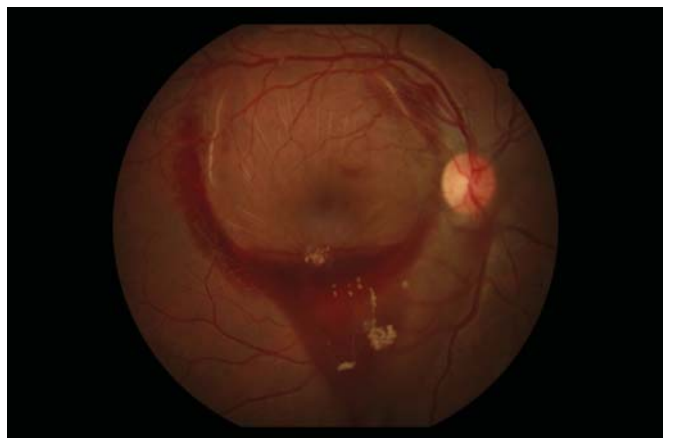

Fig. 3: Picture of the first post treatment day.

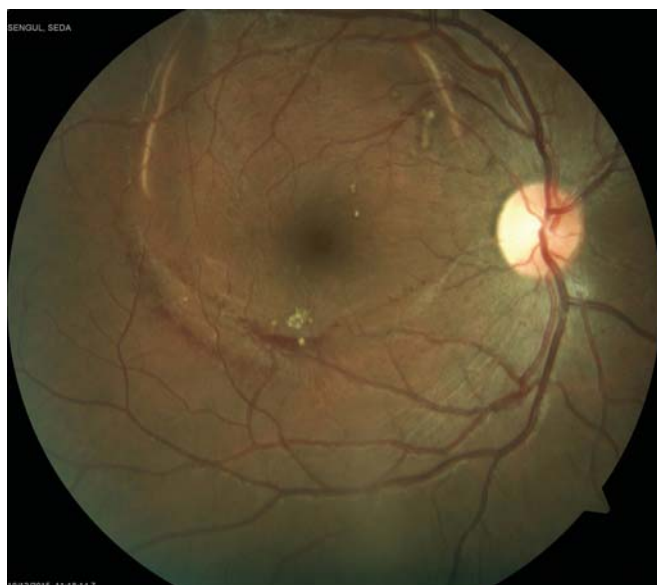

Fig. 4: Picture After one month.

air injection but after this treatment the patient must stay prone position, risk of complication is higher than laser treatment.¹⁶ Argon laser hyaloidotomy is being used for treatment of subhyaloid hemorrhage successfully, it works with spot size of 100 μm and energy levels ranging from 200-300 Mw.¹⁷⁻¹⁸ The power of settings vary from case to case such as in cataract or in vitreous hemorrhage. It is better to create adequate opening with least amount of power. I used it with a spot size of 100 μm , exposure duration of 0.1 seconds, 5 laser shots and power of 500 mW in order to drained the subhyaloid blood into the vitreous cavity. In my opinion, before argon laser we have to choose the most appropriate location. It is important to keep the laser beam to the inferior part of the hemorrhage so it can be darined to the vitreous more rapidly with the force of gravity and its weight . Than the patient has to be stay prone or head erect. A location away from the fovea is also prudent which can create difficulty when the inferior position of the hemor-

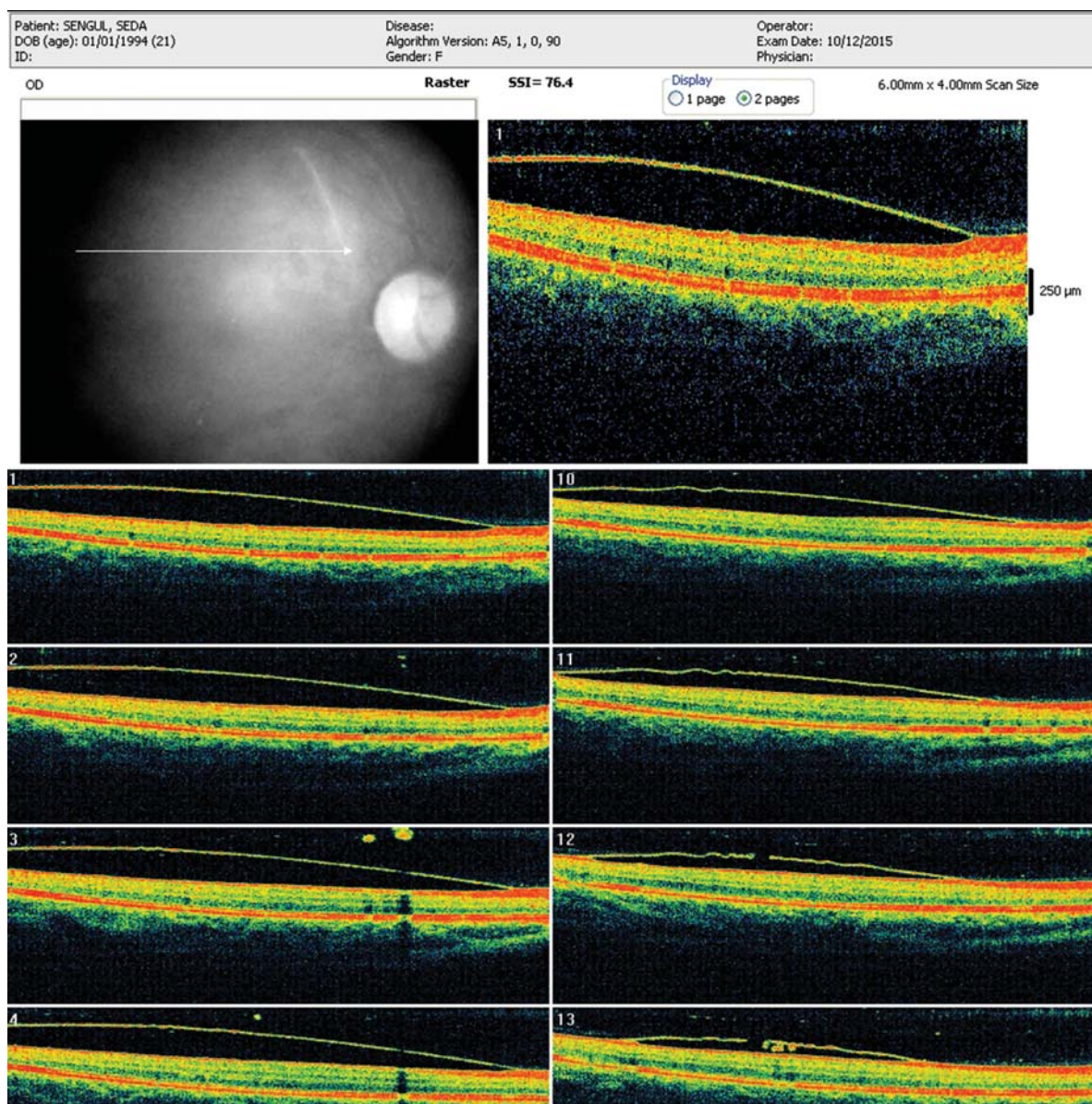


Fig. 5:

rhage is over the fovea. The choice of lens is individual, so I used Goldmann lens.

Photomechanical retinal injury can occur with the use of laser puncture resulting in macular hole, epiretinal membrane or haemorrhage (intravitreal, intraretinal or subretinal).¹⁹ In my case argon laser hyaloidotomy achieved rapid resolution of premacular subhyaloid hemorrhage without any clinical evidence of damage to the underlying retina. The patient's visual acuity improved to 1.0 (Snellen) within 1 week. This case report supports the findings of other series where Argon laser has been used to achieve rapid clearance of subhyaloid hemorrhage.²⁰

OCT can be used to show the change in ILM, hyaloid membrane and retina after laser treatment. Sabella et al. identified the location of the laser photodisruption on spectral domain OCT and there was no damage to the underlying retina.²¹ Hua et al. showed the decrease of ILM elevation on OCT during follow-up patients.²² We didn't find any damage underlying the retina or ILM elevation decreased on OCT after laser treatment.

Argon laser hyaloidotomy is shown to be a safe, effective procedure and has low risk of complications. It produces rapid dispersion of subhyaloid hemorrhage, with restoration of visual function, without a more invasive vitreoretinal procedure. This is important for patients requiring rapid visual rehabilitation to be able to continue working and psychological relief.

REFERENCES/KAYNAKLAR

- 1- Celebi S, Kukner AS. Photodisruptive Nd:YAG laser in the management of premacular subhyaloid hemorrhage. *Eur J Ophthalmol.* 2001; 11: 281-6.
- 2- Meyer CH, Mennel S, Rodrigues EB, Schmidt JC. Persistent premacular cavity after membranotomy in valsalva retinopathy evident by optical coherence tomography. *Retina.* 2006; 26: 116-8.
- 3- Chandra P, Azad R, Pal N, Sharma Y, Chhabra S. Valsalva and Purtscher's retinopathy with optic neuropathy in compressive thoracic injury. *Eye.* 2005; 19: 914-915.
- 4- Georgiou T, Pearce I, Taylor R. Valsalva retinopathy associated with blowing balloons. *Eye.* 1999; 13: 686-687.
- 5- T. D. Duane. Valsalva hemorrhagic retinopathy. *Transactions of the American Ophthalmological Society.* 1972; 70: 298-313.
- 6- Duke-Elder S, Dobree JH. *System of Ophthalmology.* 1967; 10: 145-7.
- 7- Gabel VP, Birngruber R, Gunther-koszka H, Puliofito CA. Nd:YAG laser photodisruption of hemorrhagic detachment of the internal limiting membrane. *Am J Ophthalmol.* 1989; 107: 33-7.
- 8- Ramsay RC, Knobloch WH, Cantrill HL. Timing of vitrectomy for active proliferative diabetic retinopathy. *Ophthalmology.* 1986; 93: 283-289.
- 9- Fechner PU. Premacular hemorrhage: a new indication for argon laser therapy. *Klin Monatsbl Augenheilkd.* 1980; 177: 502-505
- 10- Perez-Rico C, Montes-Mollon A, Castro-Rebollo M, et al. Optical coherence tomography features of sub-internal limiting membrane hemorrhage and temporary premacular cavity following Nd-YAG laser membranotomy in valsalva retinopathy. *Jpn J Ophthalmol.* 2008;52:513-5.
- 11- Duane TD. Valsalva hemorrhagic retinopathy. *Am J Ophthalmol.* 1973; 75: 637-42
- 12- Ulbig MW, Mangouritsas G, Rothbacher HH, et al. Long-term results after drainage of premacular subhyaloid hemorrhage into the vitreous with a pulsed Nd:YAG laser. *Arch Ophthalmol.* 1998; 116: 1465-9.
- 13- Kaynak S, Eryildirim A, Kaynak T, Durak I, Saat O, Eryildirim S & Ozcan Y. Nd:YAG laser posterior hyaloidotomy in subhyaloid hemorrhage. *Ophthalmic Surg.* 1994; 25: 474-476.
- 14- Durukan A. H., Kerimoglu H., Erdurman C., et al. Long-term results of Nd: YAG laser treatment for premacular subhyaloid haemorrhage owing to Valsalva retinopathy. *Eye.* 2008;22: 214-218.
- 15- O'Hanley GP, Canny CLB. Diabetic dense premacular hemorrhage: a possible indication for prompt vitrectomy. *Ophthalmology.* 1985; 92:507-11.
- 16- Chung J, Park YH, Lee YC. The effect of Nd:YAG laser membranotomy and intravitreal tissue plasminogen activator with gas on massive diabetic premacular hemorrhage. *Ophthalmic Surg Lasers Imaging.* 2008; 39: 114-20.
- 17- Ozertürk Y, Durmuş M, Bardak Y. Argon laser posterior hyaloidotomy in subhyaloid haemorrhage. *Ret-Vit.* 2002;10
- 18- Sahu, Dinesh K, Namperumalsamy P, Kim R. Argon laser treatment for premacular hemorrhage. *Retina.* 1998; 18: 79-81
- 19- Kwok AK, Lai TY, Chan NR. Epiretinal membrane formation with internal limiting membrane wrinkling after Nd: YAG laser membranotomy in valsalva retinopathy. *Am J Ophthalmol.* 2003; 136: 763-766.
- 20- Tetikoğlu M, Erdokur O, Öztürk M, Dicle D, Elçioğlu M. Argon Laser Therapy in Premacular Subhyaloid Haemorrhages. *Ret-Vit.* 2010; 18: 61-64
- 21- Sabella P, Bottoni F, Staurengi G. Spectral-domain OCT evaluation of Nd:YAG laser treatment for Valsalva retinopathy. *Raefes Arch Clin Exp Ophthalmol.* 2010; 248: 599-601
- 22- Hua R, Liu L, Hu Y, Zhou Y, Chen L. Combine intravitreal bevacizumab with Nd: YAG laser hyaloidotomy for valsalva pre-macular haemorrhage and observe the internal limiting membrane changes: aspectralis study. *Int J Ophthalmol.* 2013; 6: 242-245